

Chapter 5.6

Neural Control and Coordination

In all the multicellular animals above the level of sponges, the system meant to perceive stimuli detected by the receptors, to transmit these to various body parts, and to effect responses through effectors, is called *nervous system*. In vertebrates, it is highly specialized and plays at least three vital roles

(1) **Sensory function** : It senses certain changes (stimuli) both within body (internal environment) and out side body (external environment).

(2) **Integrative functions** : It analyses the sensory information, store some aspects, and make decisions regarding appropriate behaviour.

(3) **Motor functions** : It may respond to stimuli by initiating muscular contractions or glandular secretions.

Nervous systems in various animals

(1) **Coelenterata** : True nerve cell or ganglion cells occur for the first time in coelenterates. They are derived from interstitial cells of epidermis, forming nerve net or nerve plexus below whole epidermis. A polar neurons are found in coelenterata.

(2) **Platyhelminthes** : Nervous system of planarians marks the beginning of a centralized nervous system encountered in higher animals. That is made up of brain or cerebral ganglia, two lateral longitudinal nerve chords, numerous peripheral nerves and transverse commissures or connectives. This is sometimes called the ladder type of nervous system.

In Nematoda (e.g. *ascaris*) these system made up of central nervous system, peripheral nervous system and rectal nervous system. Rectal nervous system more developed in male. *Ascaris* with dorsal, ventral, and lateral nerve cords.

(3) **Annelida** : Nervous system well developed and concentrated. It consists of three parts : central nervous system, peripheral nervous system and sympathetic nervous system, central N.S. made up of Nerve ring and ventral nerve cord. Nerves are of mixed type, consisting of both afferent (sensory) and efferent (motor) fibres.

(4) **Arthropoda** : The nervous system of prawn or arthropod is of the annelidan type. However it is somewhat larger and has more fusion of ganglia. It consists of (i) The central nervous system including brain connected with a ventral ganglionated nerve cord through a pair of circum-oesophageal commissures, (ii) The peripheral nervous system including nerves and (iii) The sympathetic nervous system. In arthropods like cockroach sympathetic nervous system also known as stomatogastric nervous system, made up of 4 ganglion and retro-cerebral complex.

(5) **Mollusca** : In gastropodes (e.g. *pila*) consists of paired ganglia, commissures and connective uniting them and nerves running from these central organs to all parts of the body. It has various type of ganglia as cerebral, buccal, pleuro-pedal, supra intestinal and visceral etc. In palecyopoda nervous system is greatly reduced due to sluggish and sedentary mode of life and there is little evidence of the brain. But in cephalopoda shows a high grade of organization attained only by some insects and arachnids among the other invertebrates.

(6) **Echinodermata** : Echinodermites has simple and primitive type of nervous system. It has the form of a nerve net, consisting of nerve fibres and a few ganglion cells, all confined to the body wall except the visceral nerve plexus situated in the gut wall. At certain places the nervous tissue is concentrated to form distinct nerve cords. It is made up of (i) Superficial or ectoneural nervous system (ii) Hyponeural or deep nervous system (iii) Aboral or coelomic nervous system and (iv) Visceral nervous system.

(7) **Hemichordata** : Nervous system is of primitive type resembling that of coelenterates and echinodermites, with both dorsal and ventral nerve cord.

(8) **Chordates** : Nervous system well developed and formed by ectoderm. It is formed by central nervous system, peripheral nervous system and autonomic nervous system.

Development of central nervous system in human

Nervous system begins developing early in third week of development from ectoderm. Nervous tissue also develop from ectoderm except microglial cell, develop from mesoderm. The central nervous system of vertebrates includes the brain and the spinal cord. These are derived from a longitudinal mid-dorsal ectodermal thickening of the embryo, called the medullary or neural plate. This neural plate or neural groove is converted by fusion into a closed mid-dorsal longitudinal neural tube lying above the notochord. Histologically, the embryonic neural tube exhibits three zones of cells.

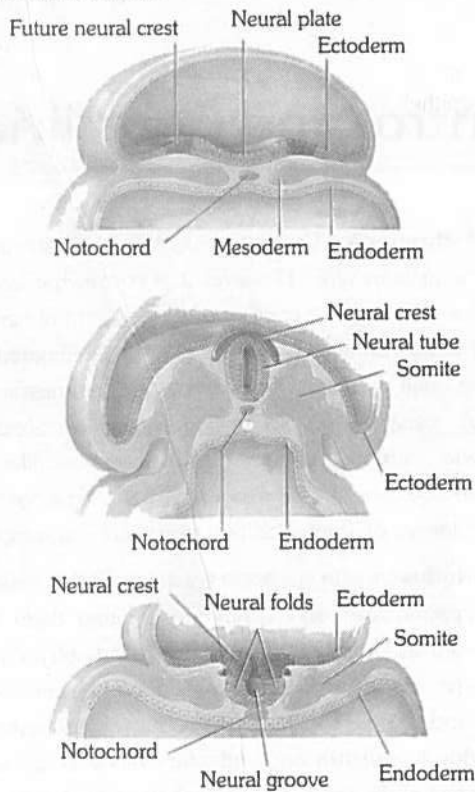


Fig : 5.6-1 Stages in the embryonic development of central nervous system

(1) **Germinal layer** : These are actively dividing cells lining the neural canal. They form the connective tissue lining of neural canal, called *ependyma*, and ventricles of brain.

(2) **Mantle layer** : It consists of embryonic neurons or *nematoblasts*, forming the grey matter.

(3) **Marginal layer** : It consists of nerve fibres, mostly surrounded by fatty myelin sheaths, and forms the *white matter*. Neurons and fibres are supported by a special connective tissue of ectodermal origin, the *neuroglia*, cells of which become increasingly abundant and diversified in higher vertebrates.

Development of brain

The anterior end of embryonic neural tube is already enlarged forming the embryonic brain, called *encephalon*. By differential growth and two constrictions, it is divided into a linear series of three *primary cerebral vesicles*, termed the *forebrain*, *midbrain* and *hindbrain*. These give rise to the three major divisions of the adult

brain – (1) *prosencephalon* (forebrain), (2) *mesencephalon* (midbrain), and (3) *rhombencephalon* (hindbrain). These further become subdivided into 5 subdivisions. Prosencephalon divides into an anterior telencephalon and posterior diencephalon; the mesencephalon remain unchanged. The rhombencephalon divides into an anterior metencephalon and a posterior myelencephalon. Ultimately, telencephalon develops into cerebral hemisphere and basal ganglia and houses lateral ventricle. Diencephalon develops into thalamus, hypothalamus, and pineal gland and houses the third ventricle. Mesencephalon develops into mid brain and houses cerebral aqueduct. Metencephalon develops into pons and cerebellum; and myelencephalon develops into medulla oblongata, houses 4th ventricle. The area of neural tube inferior to myelencephalon gives rise to spinal cord.

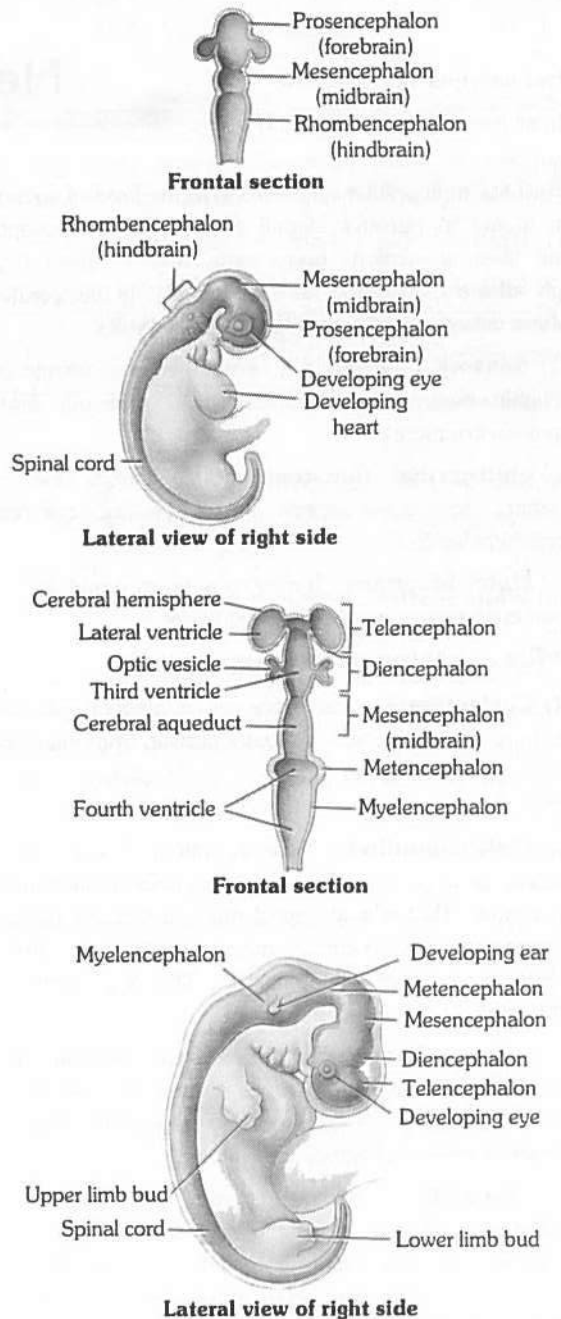
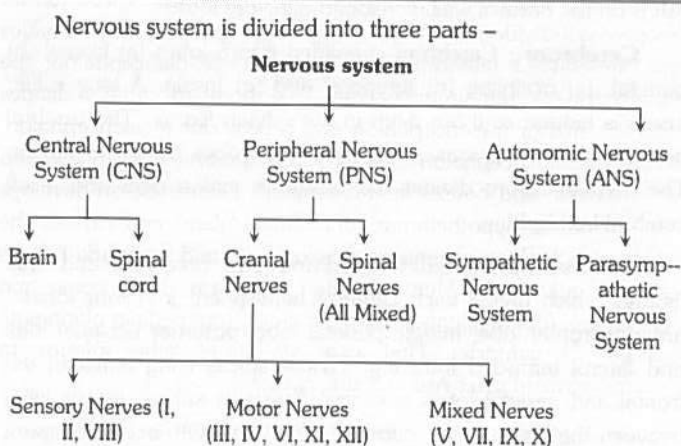


Fig : 5.6-2 Development of the brain and spinal cord

Parts of nervous system



Central nervous system (CNS)

In all the vertebrates including man, CNS is dorsal, hollow and non-ganglionated while in invertebrates when present, it is ventral, solid, double and ganglionated. CNS is formed of two parts :

(1) **Brain** – Upper and broader part lying in the head.

(2) **Spinal cord** – Lower, long and narrow part running from beginning of neck to trunk. CNS is covered by 3 meninges and its wall has two type of matter.

Types of matter : CNS of vertebrates is formed of two types of matter –

(i) **Grey matter** : It is formed of cell-bodies, non-medullated nerve fibres, neuroglia, dendrites of association neurons and motor neurons.

(ii) **White matter** : It is formed of medullated nerve fibres or myelinated axon of motor and sensory neurons, which appear white due to the presence of medullary sheath.

Meninges : The meninges are connective tissue membranes which surround the brain and spinal cord of CNS. In the fishes, there is only one meninx called meninx primitiva (pia mater). In amphibians, reptiles and birds, the brain is covered by two meninges or membranes : inner pia-arachnoid and outer duramater. In mammals, CNS is covered by three meninges or membranes or cranial meninges. Brain meninges are continuous with spinal meninges

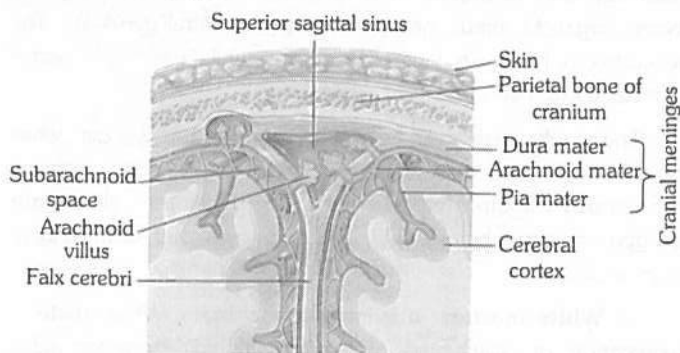


Fig : 5.6-3 Meninges of brain

The three layers of cranial meninges in order from superficial to deeper duramater, arachnoid and pia mater. Duramater is nonvascular, tough made up of fibrous connective tissue. Arachnoid mater made up of reticular connective tissue with collagen and elastin fibre, while innermost vascular pia mater (nutritive) made up of loose areolar connective tissue. Between dura and arachnoid mater presence of sub dural space (no CSF in mammals here), between Arachnoid and pia mater presence of sub-arachnoid space (with CSF in mammals, CSF also found in ventricles and central canal). Between duramater and periosteum presence of epidural space. An extension of duramater between two cerebral hemispheres is called falx cerebri. Tentorium, an extension of duramater between cerebrum and cerebellum.

Cerebrospinal fluid : All the ventricles of the brain, central canal of spinal cord are continuous and lined by a columnar, ciliated epithelium, the ependyma. They contain lymph-like extracellular fluid called the cerebrospinal fluid (C.S.F.). This fluid is secreted by the choroid plexuses by filtration of blood. The choroid plexuses consist of loose connective tissue of pia mater covered internally by a simple cuboidal epithelium of secretory (glandular) nature. The cerebrospinal fluid slowly flows toward the fourth ventricle by secretion pressure and passes into the spinal cord. Some fluid escapes into the subarachnoid spaces through three pores a median aperture (of magendie) and a paired lateral aperture (of Luschka) in the roof of the fourth ventricle in the medulla. From the subarachnoid spaces, the cerebrospinal fluid is transferred to the blood of the venous sinuses. Nervous tissue is without lymphatic vessels.

The cerebro-spinal fluid (CSF) provides –

- (i) Protection to brain from mechanical shocks, physical injury.
- (ii) Optimum physiological fluid environment for neural functions e.g. conduction of nerve impulses, transport of aminoacids, sugars, O_2 etc.
- (iii) 'Relief' mechanism for the increase in intracranial pressure that occurs with each arterial pulse of blood to brain.
- (iv) 'Sink' like facility for metabolites of brain.
- (v) The blood CSF barrier for selective transport process between blood and CSF.
- (vi) Nourishment to CNS.

Major site of CSF formation is choroid plexus, and mid ventricular wall and sub-arachnoid wall also contribute. CSF is cell free, slightly alkaline, and is isotonic to plasma. Rate of formation of C.S.F is 20 ml/h (480 ml/day) approx, 1/2 litre per day. Total amount present in and around CNS is 80-150 ml it means there is atleast 3 times renewal of C.S.F. every day. CSF contains glucose, proteins, lactic acid, urea, Na^+ , K^+ , Ca^{2+} , Mg^{2+} , Cl^- , HCO_3^- and some WBC.

Blood brain barrier facilitate maintenance of stable internal environment. It acts as physiological and pathological barrier.

□ **Hydrocephalus** : The enlargement of head, a pathological condition characterized by an abnormal accumulation of cerebrospinal fluid resulting in headache, vomiting, pain and stiffness of the neck.

- ❑ Increased cerebrospinal fluid may result in Meningitis.
- ❑ Meningitis may occur due to infection and inflammation of meninges or injury of meninges.
- ❑ Infection may be viral, bacterial or both. The most common cause of meningitis is the infection of *Streptococcus pneumoniae*, *Neisseria meningitidis* and *Haemophilus influenzae*.
- ❑ Lumbar puncture is done for drainage of excess of cerebrospinal fluid during meningitis.
- ❑ Cerebro-spinal fluid is formed by choroid plexus (ACP and PCP).

There are three choroid plexus in humans –

- (i) **Lateral choroid plexus** : It is in the roof of I and II ventricle.
- (ii) **Anterior choroid plexus** : It is in the roof of III ventricle (diocoel).
- (iii) **Posterior choroid plexus or pelochoroida** : It is in the roof of IV ventricle.

Oxygen and glucose requirements : Brain controls the functions of our body organs and also provides the qualities of mind – learning, reasoning, and memory. For these activities, brain needs a large and constant energy supply. At any given time, the activities of the brain account for 20% of the body's consumption of oxygen and 15% of its consumption of blood glucose. Brain deprived of oxygen for just 5 minutes is permanently damaged. Mental confusion results if brain is deprived of glucose.

Structure of human brain (Encephalon)

It is soft, whitish, large sized and slightly flattened structure present inside cranial cavity of cranium of the skull. In man, it is about 1200-1400 gm in weight and has about 10,000 million neurons. Brain is made up of 3 parts :

- (1) **Fore brain or Prosencephalon** : It forms anterior two-third of brain and is formed of three parts.

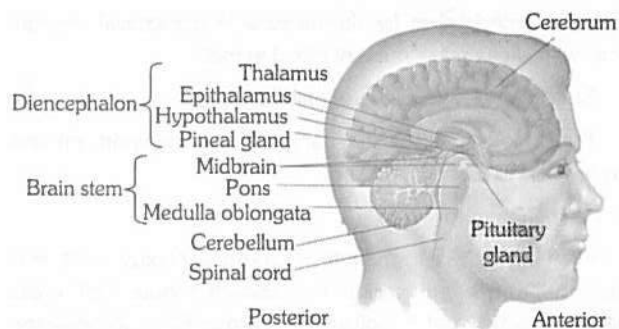


Fig : 5.6-4 Main parts of human brain visible from lateral view

Olfactory lobes : These are one pair, small sized, club-shaped, solid, completely covered by cerebral hemisphere dorsally. Each is differentiated into two parts –

- (i) **Olfactory bulb** : Anterior, swollen part, and
- (ii) **Olfactory tract** : Posterior and narrow part which ends in olfactory area of temporal lobe of cerebral hemisphere.

Function : These control the smell.

- (a) It is normal in frog, rabbit and man.
- (b) It is well developed in dog. So power of smell is more in dog.

- (c) These are also well developed in dog fish and name dog fish is on the basis of well developed olfactory lobes.

Cerebrum : Cerebrum is divided into 5 lobes (a) frontal (b) parietal, (c) occipital, (d) temporal and (e) Insula. A lobe called insula is hidden as it lies deep in the sylvian fissure. The cerebral hemisphere are separated from olfactory lobes by rhinal fissure. The median fissure divides the cerebrum into a right and a left cerebral hemisphere.

A few sulci are well developed and form three deep and wide fissures which divide each cerebral hemisphere into four lobes : anterior frontal lobe, middle parietal lobe, posterior occipital lobe and lateral temporal lobe e.g. Fissure sulcus lying between the frontal and parietal lobes is central fissure or sulcus, that is lying between the parietal and occipital lobes is parieto-occipital fissure and that demarcating frontal and parietal lobes from the temporal lobe is lateral or Sylvian fissure. Each cerebral hemisphere is with a fluid-filled cavity called lateral ventricle or paracoel.

Two cerebral hemispheres are interconnected by thick band of transverse nerve fibres of white matter called corpus callosum. The peripheral portion of each cerebral hemisphere is formed of grey matter and is called cerebral cortex, while deeper part is formed of white matter and is called cerebral medulla. Cerebral cortex is the highest centre for many sensations and activities and is with a number of sensory areas. Cerebral cortex 2-4 mm thick.

Histology of cerebrum : The whole brain possess grey matter outside and white matter inside around ventricle.

- (i) **Grey matter** : In cerebrum grey matter is very much developed, it is on an average 2-4 mm. thick but at poles its thickness is 1.3 mm. It is thickest at pre central gyrus (4.5 mm thick). Grey matter of cerebrum is called cortex or pallium. Phylogenetically or evolutionarily cortex is divided into 3 parts –

(a) **Allocortex or paleocortex** : It is the cortex of olfactory area of frontal lobe and olfactory bulbs. In lower vertebrates (cartilagenous fish) olfactory lobes occupy most of the part of cerebrum. So in these animals sense of olfaction is very-very much developed. Sense of olfaction is oldest sense.

(b) **Mesocortex** : It is relatively not much older in development.

(c) **Neocortex or neopallium or isocortex or neencephalon** : It is most recent cortex and is developed maximum only in human. It is in prefrontal cortex or prefrontal region (organ of mind), precentral and postcentral gyrus etc. The neocortex is having 6 layer of neurons while remaining cortex possess only 5 layers.

The cerebral cortex is having area of about 2200 cm² while the cranial cavity is only 1450 cm³, so to accomodate cerebrum there appears foldings in the cortex. The ridges are called gyrus (or gyri) or convolution while the depression are called sulcus (sulci in plural).

- (ii) **White matter** : It is inner part of brain. White matter is aggregation of myelinated and unmyelinated axons of many neurons. Its fibres are divided into 3 categories :

(a) **Commissural fibres** : These neurons connect gyri of 2 hemispheres, such as corpus callosum, habenular commissure, anterior commissure, posterior commissure.

(b) **Associate fibres** : They connect gyri of same hemisphere.

(c) **Projection neuron** : They are infact ascending and descending nerve tract, they connect one part of brain to another part of brain or to spinal cord. (In spinal cord they were called as column).

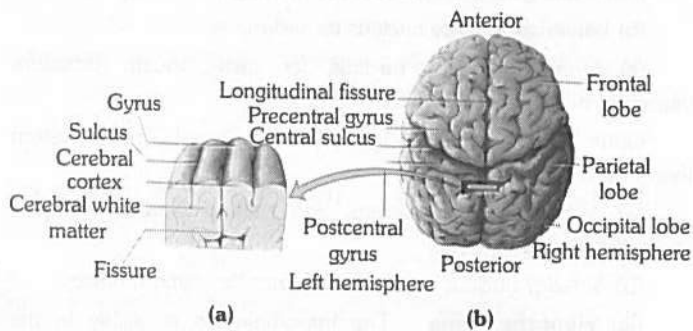


Fig : 5.6-5 (a) Details of gyrus, sulcus and fissure, (b) Posterior superior view of cerebrum

Associated structures of cerebrum : Cerebrum has following specific structure.

(i) **Sub cortex** : Nuclei on white matter. It is cluster of grey neurons in depth of white matter, they are formed in whole brain and are named differently.

(ii) **Basal ganglia or central nucleus** : These are several groups of nuclei in each cerebral hemisphere.

Corpus striatum : Corpus striatum is the largest nucleus, consist of caudate nucleus and lenticular nucleus. The lenticular nucleus is sub-divided in putamen (outer shell) and globus pallidus (ball). Other structure, functionally linked to and some times considered part of basal ganglia are :

(a) **Clastrum** : It is the name given to grey matter present between insula and putamen.

(b) **Epistriatum or Amygdaloid body** : It is structure present at the end of caudate nucleus.

(c) **Red nucleus and substantia nigra** of mid brain.

(d) **Sub thalamic nuclei of diencephalon.**

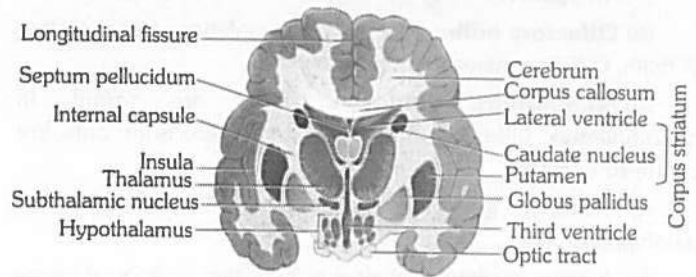


Fig : 5.6-6 Basal ganglia

Function of basal ganglia

(i) Caudate and putamen control large automatic movements of skeletal muscle like swinging of arm while walking.

(ii) Globus pallidus control muscle tone for specific body movements.

(iii) **Corpus callosum** : It is the band of white neurons present between both cerebral hemisphere and connect them on medial surface. It is present only in mammal. It has anterior part genu, middle part trunchus and last part splenium.

Below corpus callosum there are two fused band of white neurons called fornix. There anterior part is called column and posterior part is called crura. Between column and genu a membrane is called septum lucidum or septum pellucidum. Septum lucidum encloses a space called V_5 or Pseudocoel, because it is not possessing C.S.F. i.e. why it is called pseudocoel.

(iv) **Limbic system** : Limbic system present on inner border of cerebrum and floor of diencephalon, It is also called emotional brain or animal brain. Limbic system controls emotion, animal behaviour like chewing, licking, sniffing, docility, tameness, affection (animals) rage, pain, pleasure, anger, sexual feelings, fear, sorrow grooming. It has following structure –

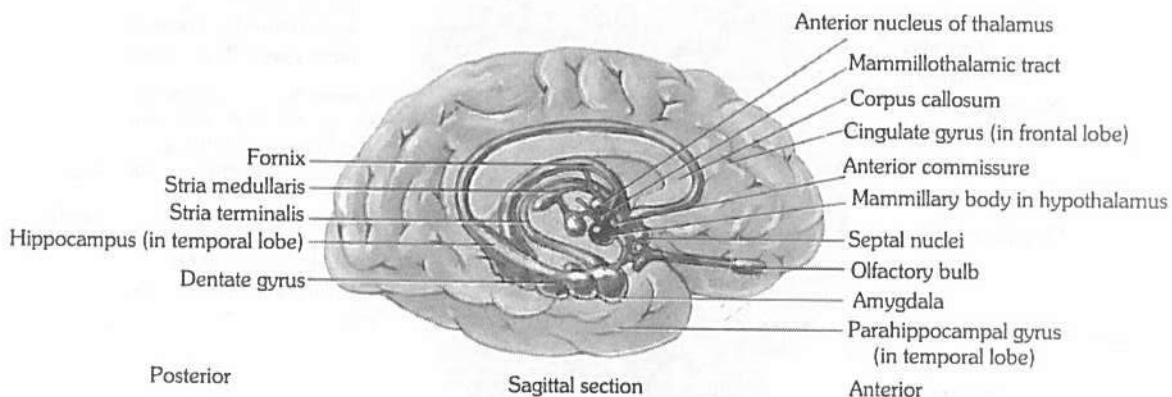


Fig : 5.6-7 Components of limbic system and surrounding structure

950 Neural Control and Coordination

- (a) **Cingulate gyrus** : It is a region of pre central gyrus.
- (b) **Hippocampal gyrus** : It is a region of temporal lobe near colossomarginal sulcus. These two structure are combinely called limbic lobe.
- (c) **Amygdaloid body** : It is the end of caudate nucleus.
- (d) **Olfactory bulb** : They are on the inferior anterior surface of brain. Olfactory nerve ends in these bulb.
- (e) **Mammillary body** : They are found in hypothalamus. Olfactory bulb and mammillary body both are centre of olfaction.
- (f) **Dentate gyrus** : Is in between hippocampus and parahippocampale.
- (g) Anterior nucleus of thalamus is located in floor of lateral ventricle.

Diencephalon : Diencephalon cavity is called, III ventricle or diocoel the thin roof of this cavity is known as the epithalamus, the thick right and left sides as the thalami, and floor as the hypothalamus.

(i) **Epithalamus** : It forms the roof of third ventricle. The epithalamus is not formed of nervous tissue. It consists of piamater only. Hence, it is of relatively little significance as a nerve centre. Its anterior part is vascular and folded. It is called anterior choroid plexus. Behind this plexus, the epithalamus gives out a short stalk, the pineal stalk which bears a small, rounded body, the pineal body, at its tip, and paired right and left habenular nuclei (olfaction or smell).

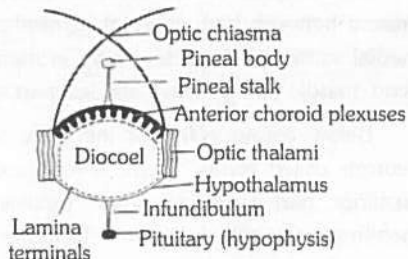


Fig : 5.6-8 Diencephalon

(ii) **Thalamus** : A pair of mass of grey matter forms the superior part of lateral walls of the third ventricle. It measures 3 cm in length and comprises 80% of diencephalon. The thalamus is principal relay station for sensory impulses that reach the cerebral cortex from spinal cord, brain stem, cerebellum. It also allows crude appreciation of some sensations such as pain, temperature, and pressure. Certain nuclei in the thalamus relay all sensory input to cerebral cortex. These include the –

- Medial geniculate nucleus for hearing.
- Lateral geniculate nucleus for vision.
- Ventral posterior nucleus for taste, touch, pressure, vibration, heat, cold, and pain.

Other nuclei are centres for synapse in somatic motor system their include.

(a) Ventral lateral nucleus and ventral anterior nucleus (voluntary motor actions).

(b) Anterior nucleus concerns with emotions and memory.

(iii) **Hypothalamus** : The hypothalamus is visible in the ventral view of the brain and forms the floor of diencephalon. Hypothalamus also gives a nervous process called infundibulum (forms pars nervosa) which meets a rounded non-nervous pharyngeal outgrowth called hypophysis. Both collectively form master gland called pituitary body. A stalked outgrowth of infundibulum combines with a pouch-like epithelial outgrowth (Rathke's pouch) of the roof of embryonic mouth (= stomadeum), forming a pituitary gland or hypophysis. Which secretes a number of hormones. In front of hypothalamus, there is crossing of two optic nerves called optic chiasma. Behind the hypothalamus, there is one pair of small, rounded, nipple-like bodies called mammillary bodies or corpora mammillares. The hypothalamus consists of many masses of grey matter, called hypothalamic nuclei, scattered in the white matter.

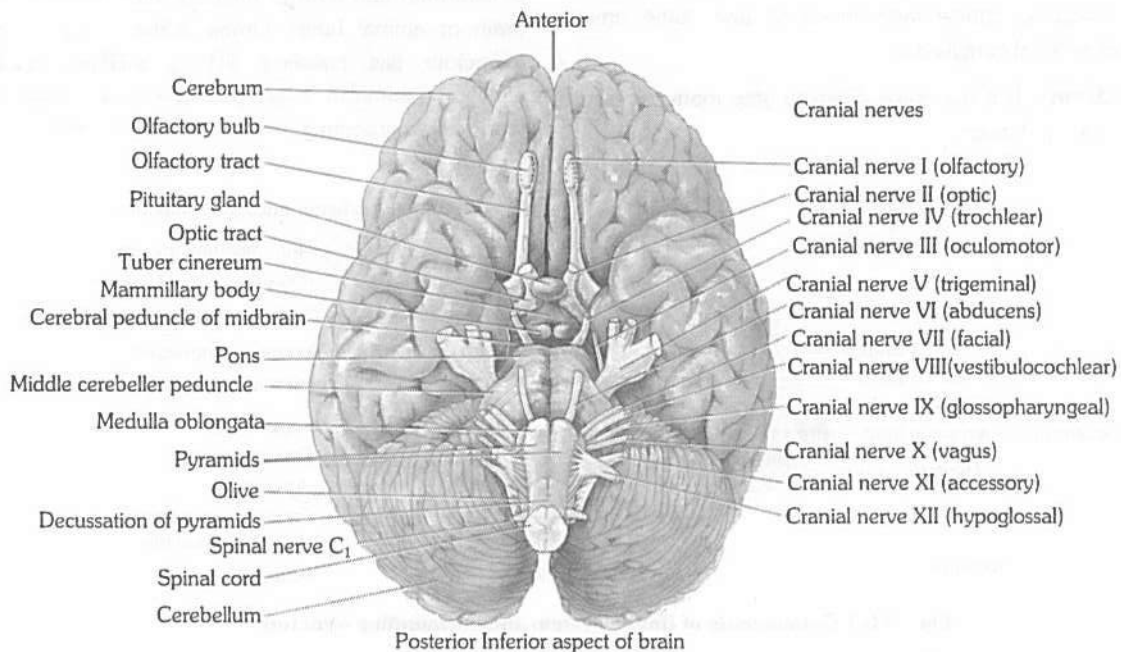


Fig : 5.6-9 Ventral view of brain

In man and some other mammals, most fibres of optic nerves cross, but some fibres do not cross and innervate the eyes of their own respective sides. This arrangement enables man and these mammals to have a binocular vision. Rabbits simply have a monocular vision.

Pineal gland is a pine cone-shaped gland. It is located in the centre of brain with which it loses all nervous connection after birth. It is innervated by sympathetic nerves. It has a photosensory role in amphibian and primitive reptiles and is called 'Third eye'. Pinealocytes secrete melatonin. Mammalian pineal does not act as photoreceptor but it produces the hormone called melatonin which is anti FSH, and anti LH. It inhibits reproductive function. Melatonin secretions decrease after puberty.

Functions of fore brain

(i) **Olfactory lobe** : It is centre of smell.

(ii) **Cerebrum** : Cerebral cortex is made up of grey matter and differentiated into –

(a) **Sensory and associated area** confirm, recognise and evaluate for shape, colour, sound, taste and smell for sensory cells in relation with object.

(b) **Broca's area** : Known as sensory speech area or motor speech area. Translate thought into speech. Located into frontal lobe towards left side. It is associated with language area and also

interpret translation of written words into speech. Damage or injury in Broca's area (sensory or motor speech area) may result.

Aphasia(Inability to speak), Word deafness, Word blindness.

Table : 5.6-1 Important areas in the human brain

Area	Location	Function
Premotor area	Frontal lobe	The highest centre for involuntary movements of muscles and ANS.
Motor area	Frontal lobe	Controls voluntary movements of the specific muscle
Broca's area	Frontal lobe	Motor speech area (Translation of thought and written words into speech)
Somesthetic area	Parietal lobe	Perception of general sensation like pain, touch and temperature
Auditory area	Temporal lobe	Hearing (Interprets characteristics of sound such as pitch and rhythm.
Olfactory area	Temporal lobe	Sense of smell
Wernicke's area	Temporal lobe	Understanding speech, written and spoken
Gustatory area	Parietal lobe	Sense of taste
Visual area	Occipital lobe	Sensation of light

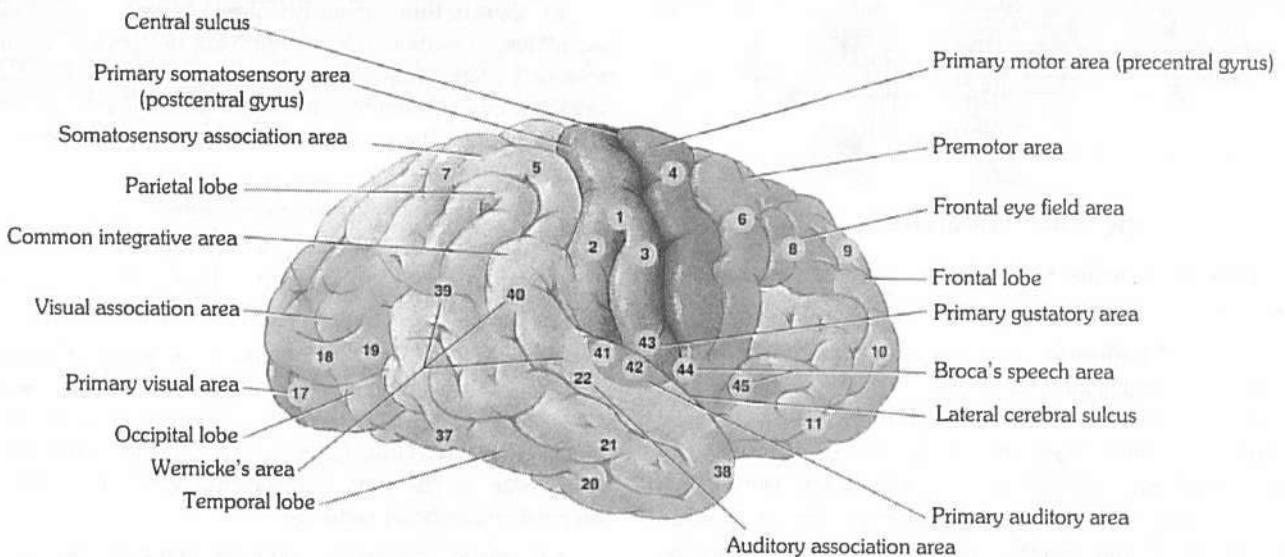


Fig : 5.6-10 Functional areas of the cerebrum

(c) **Cerebrum is a centre for** – Intelligence, Emotion, Will power, Memory, Consciousness, Imagination, Experience, Knowledge, Reasoning, Voluntary controls, Weeping and laughing, Micturition, Defecation.

If cerebrum is removed animal becomes simple reflex animal.

(iii) **Diencephalon is a centre for :**

(a) Carbohydrate metabolism

(b) Fat metabolism

(c) It relays impulses from posterior region of brain and also to posterior region of brain.

- (d) It secretes neurohormone
- (e) Form part of pituitary gland
- (f) Secrete cerebrospinal fluid

(iv) **Hypothalamus is a centre for** – Hunger, Thirst, Sweating, Sleep, Fatigue, Temperature, Anger, Pleasure, love and hate, Satisfaction.

- It is also centre to release factors for endocrine glands.
- It also control A.N.S (autonomic nervous system)
- Centres for regulation of parasympathetic (cranio-sacral) activity. When stimulated, it causes slowing down of heart beat, contraction of the visceral muscles.

(2) **Mid brain or mesencephalon** : Extends from pons to diencephalon, contain both white and grey matter. Posterior portion of mid brain is called tectum. It is also completely covered by cerebral hemisphere. It is formed of two parts –

(i) **Optic lobes** : These are one pair, large sized lobes present on dorsal side. Each is divided transversely into upper and larger superior colliculus and lower and smaller inferior colliculus. So there are four optic lobes, so called optic quadrigemina (only in mammals). In frog these are known as bigemina. **Valve of vieussens**. It joins the optic lobe with cerebellum.

(a) **Superior optic lobe or superior colliculus** : They are concerned with reflex action of eye, head and neck in response to visual stimulus.

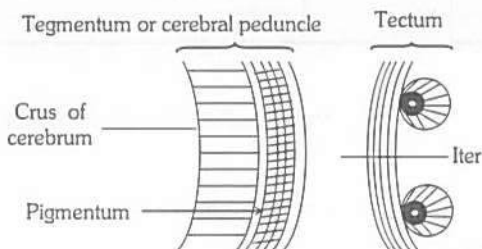


Fig : 5.6-11 Lateral view

(b) **Inferior colliculus** : They are concerned with movement of head and trunk in response to hearing stimulus.

(ii) **Cerebral peduncle (crura cerebri)** : They are the pair of thick bands of longitudinal nerve fiber present on the floor or ventral side of mid brain. The dorsal part of cerebral peduncle (white matter) is called Tegmentum while most ventral part (grey matter) is called crura cerebrae or crus of cerebrum. Dorsal thick wall of mid brain is known as optic tectum. Iter is between tegmentum and tectum. Cerebral peduncle are infact possessing ascending and descending tracts, connecting upper and lower region of brain.

In white matter of cerebral peduncle these are following sub cortical structure

(a) **Red nucleus or rustrum nucleus** : They are red because of rich blood supply and iron containing pigment or haemoglobin. Function with basal ganglia and cerebellum to coordinate muscular movement.

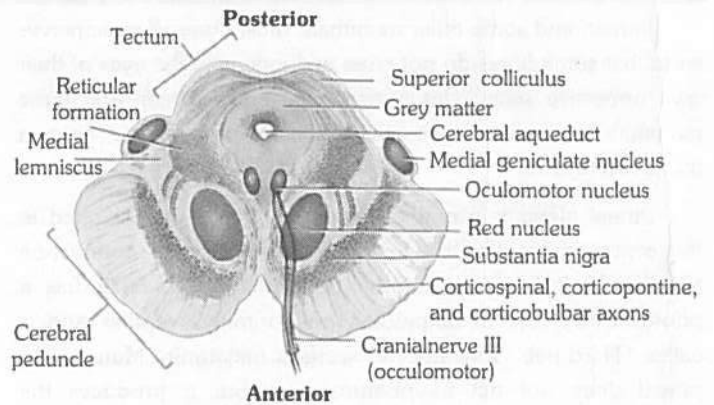


Fig : 5.6-12 T.S. of midbrain

(b) **Substantia nigra** : It is black because of much deposition of melanin.

(c) **Oculomotor nucleus** : It is origin point of 3rd cranial nerve (oculomotor) from this region 4th (Trochlear) nerve also originates.

Functions of Mid brain

- (i) Pair of anterior optic lobes (which are also known as superior colliculi) is related with vision.
- (ii) Pair of posterior optic lobe (known as inferior colliculi) related with auditory function.
- (iii) These act as coordination centres between hind and fore brain.

(3) **Hind brain** : Hind brain consists of (i) cerebellum and (ii) medulla oblongata (iii) Pons varolii.

(i) **Cerebellum (Sandwiched brain)** : Cerebellum is second largest portion of brain which lies posterior to medulla and pons and inferior to posterior portion of cerebrum. Cerebellum is separated by cerebrum by a transverse fissure and by an extension of cranial dura mater called tentorium cerebelli. Cerebellum is butterfly shape consist of :

- (a) The central constricted area is vermis
- (b) A lateral wings or lobes called cerebellar hemispheres with anterior and posterior lobe (govern skeletal muscle movement).
- (c) The flocculo nodular lobe (sense of equilibrium).

Between cerebellar hemisphere is extension of cranial dura mater called falx cerebelli. The superficial layer of cerebellum, called cerebellar cortex, consist of grey matter in series of parallel ridges called folia. Deep to grey matter is white matter tree called 'Arbor vitae' or tree of life. Cerebellum is attached to brain stem by three paired cerebellar peduncles –

- (a) Inferior cerebellar peduncle between cerebellum and medulla with sensory/motor fibre.
- (b) Middle cerebellar peduncle between cerebellum and pons with sensory axon.
- (c) Superior cerebellar peduncle between cerebellum and mid brain, mainly with major fibre.

Cerebellum receives sensory impulses from proprioceptors in muscle, joint, and tendons, coordinate skeletal muscle contractions and also regulate posture and balance.

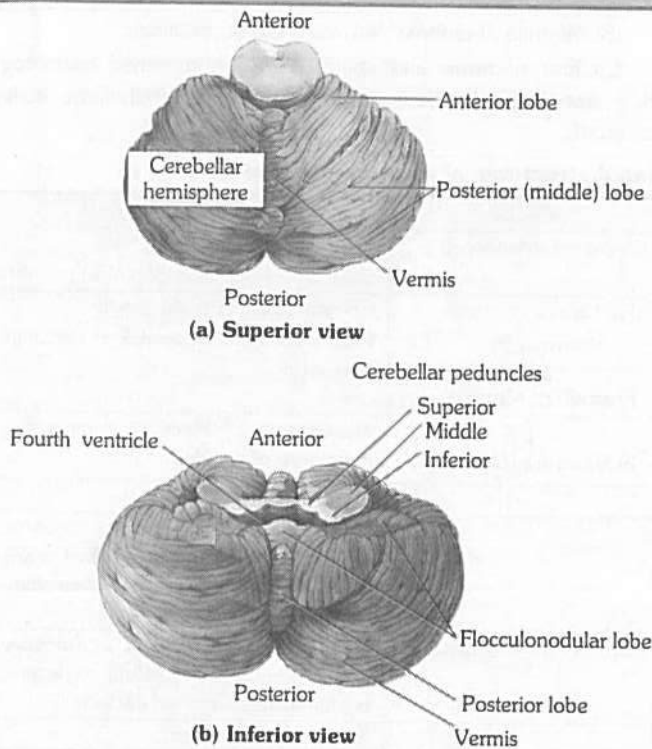


Fig : 5.6-13 Structure of Cerebellum

(ii) **Medulla oblongata**

Medulla oblongata is the hindmost and posterior most part of brain. Cavity is known as IVth ventricle (metacoel) which is continuous with central canal of spinal cord. It has a pair of lateral Foramina of Luschka and a median foramen magnum. Cerebrospinal fluid come in contact by these apertures from internal cavity of the brain to outer fluid of meninges. A arrangement on its ventral surface there are buldings of ascending and descending tract which are called pyramids. On the ventral surface these pyramids cross each other which is called decussation of pyramids. On the dorsal side of medulla there are two nuclei which are called nucleus gracilis (long) and nucleus cuneatus. On floor of V_4 there is groove called calamus scriptorius.

In the medulla oblongata, most of the sensory and motor fibres cross from one side to the other. Thus, the left cerebral hemisphere controls the right side of the body and *vice versa*. The reason for this is not known. The lower end of medulla passes into the spinal cord. There is no demarcation between the two. However, the medulla is considered to start at the level of the foramen magnum of the cranium. Medulla contain nuclei of origin of 5 pairs of cranial nerves, VIII, IX, X, XI and XII. VIII – vestibulocochlear nerve is concerned with hearing and equilibrium. (There are also nuclei for vestibular branch of VIII in pons).

(iii) **Pons Varolii** : An oval mass, of white matter called the pons varolii, lies above the medulla oblongata. It consists mainly of nerve fibres which interconnect as bridge connecting spinal cord with brain and parts of brain with each other. Pons also with pneumotaxic area and apneustic area. Together with medullary rhythmicity area, they help in controlling respiration.

Functions of hind brain

Cerebellum –

(i) Poorly developed in frog but well developed in mammal.

- (ii) It is centre for co-ordination of muscular movement.
- (iii) It is primary centre for balancing, equilibrium, orientation.

Medulla oblongata contain centre for –

- (i) Heart beats
- (ii) Respiration
- (iii) Digestion
- (iv) Blood pressure
- (v) Gut peristalsis
- (vi) Swallowing of food
- (vii) Secretion of gland
- (viii) Involuntary function – e.g. vomiting, coughing vasoconstrictor, vasodilator, sneezing, hiccupping.
- (ix) It control urination, defecation.
- (x) The cardiovascular centre – regulate rate, force of heart beats.
- (xi) Medullary rhythmicity area – adjust basic rhythm of respiration.

Cavities or ventricles of the brain

The ventricles consist of four hollow fluid filled space inside the brain and same duct for connection between these ventricle.

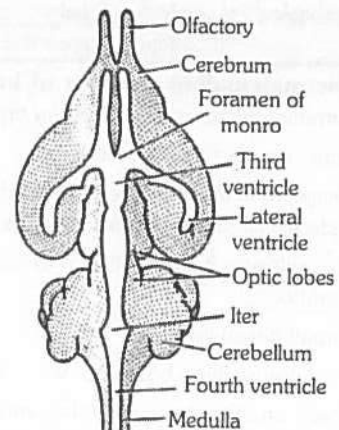


Fig : 5.6-14 Ventricles of brain of rabbit

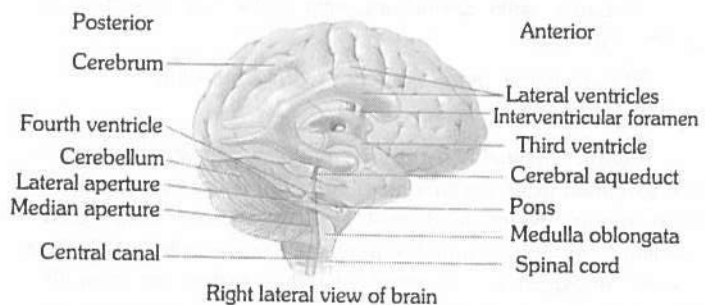


Fig : 5.6-15 Diagram showing ventricles of human brain

- (1) Olfactory lobe – Rhinocoel
- (2) Cerebrum – I and II ventricle or lateral ventricle or paracoel.
- (3) Foramen of monro : I and II ventricle communicating with IIIrd ventricle by foramen of monro. They are two in human and single in rabbit and frog.
- (4) Diencephalon : Third ventricle or Diocoel.

954 Neural Control and Coordination

(5) *Iter* or cerebral aquiduct or aquiduct of sylvius : It is very narrow cavity between III and IV ventricle.

(6) Optic lobe : Optocoel

(7) Cerebellum : Solid.

(8) Medulla oblongata : 4th ventricle or metacoel.

Cavities of brain and spinal cord are modified neurocoel. They are lined by low columnar ciliated epithelium called endoderm.

Table : 5.6-2 Subdivisions, parts and associated structures of a vertebrate brain

Divisions	Subdivisions	Parts	Cavity	Associated structures
(I) Prosencephalon (Forebrain)	(1) Telencephalon	Rhinencephalon	I Ventricle (<i>Rhinocoel</i>)	Olfactory bulbs, Olfactory tracts, Olfactory lobes, Palaeocortex on pallium
		Cerebral hemispheres	II or Lateral Ventricles (<i>Paracoels</i>) ↓ Foramen of Monro	Corpora striata or basal ganglia, Corpus callosum, Neocortex on pallium, Paraphysis
	(2) Diencephalon	Epithalamus (roof)	↓ III Ventricle (<i>Diocoel</i>)	Habenulae, Pineal apparatus, Parapineal or parietal
		Thalamus (sides) superior Hypothalamus (floor), Inferior side		Hypothalamic nuclei, Optic chiasma, Median eminence, Infundibular stalk, Pituitary, Saccus vasculosus, Mamillary bodies, Anterior choroid plexus
(II) Mesencephalon (Midbrain)	—	Crura cerebri (floor)	<i>Iter</i> or cerebral aqueduct	Corpora quadrigemina (superior colliculi, inferior colliculi), Tectum, substantia nigra and red nuclei.
(III) Rhombencephalon (Hind brain)	(1) Metencephalon	Cerebellum		Trapezoid body, Pons
	(2) Myelencephalon	Medulla oblongata	IV Ventricle (<i>Metacoel</i>)	Restiform bodies, Pyramids

Salient or mammalian features of human brain : The salient or mammalian features in the human brain are –

- (1) Relatively small, solid olfactory lobes.
- (2) Very large cerebral hemispheres divided into lobes and with highly folded surface, with cerebral cortex of grey matter.
- (3) Corpus callosum interconnecting the cerebral hemispheres only found in eutheria.
- (4) Very small pineal body.
- (5) A pair of mammillary bodies joined to hypothalamus.
- (6) Relatively small, solid optic lobes divided into 4 corpora quadrigemina.
- (7) Large, solid cerebellum, with highly folded surface and divided into lobes.
- (8) Pons varolii present anterior to the cerebellum.

Spinal cord

Present in spinal canal or vertebral canal of vertebral column. It is extended from foramen magnum to II lumbar vertebra. In new born infants, extend to 3 or 4 lumbar vertebra. Spinal cord is swollen in cervical and lumbar region which are called cervical and lumbar enlargement. The length of spinal cord ranges from 42 to 45 cm. Its diameter is about 2cm.

Structure of spinal cord

- (1) **Conus medullaris :** It is last tapering end of spinal cord, its ciliated central canal is called Vth ventricle.
- (2) **Cauda equina :** A horse tail-like collection of roots of spinal nerves at inferior end of the spinal cord. Some spinal nerves arise from inferior part of cord do not leave vertebral column at same level as they exit from spinal cord. The roots of these nerves angle inferiorly in vertebral canal from end of spinal cord like wisps of hair.

(3) **Filum terminale :** It is extension of pia mater below conus medullaris upto coccyx. In frog spinal cord also extends upto end of vertebral column.

(4) **Cisterna terminalis :** It is last dilation of subarachnoid space below 1st lumbar vertebra. It is a proper site for lumbar puncture or spinal tap, which is done to drain C.S.F out (5 to 10 ml). This C.S.F is used in diagnosing many diseases of CNS like meningitis, encephalitis, inter cranial pressure, meningococcal infection etc.

(5) **Meninges :** Like brain, spinal cord is also enclosed within three membranes. In this case duramater does not remain attached with the vertebra, instead there is a space between duramater and vertebra called epidural space. The epidural space is filled with a fluid. The distribution of duramater and pia mater in spinal cord is the same as that of brain.

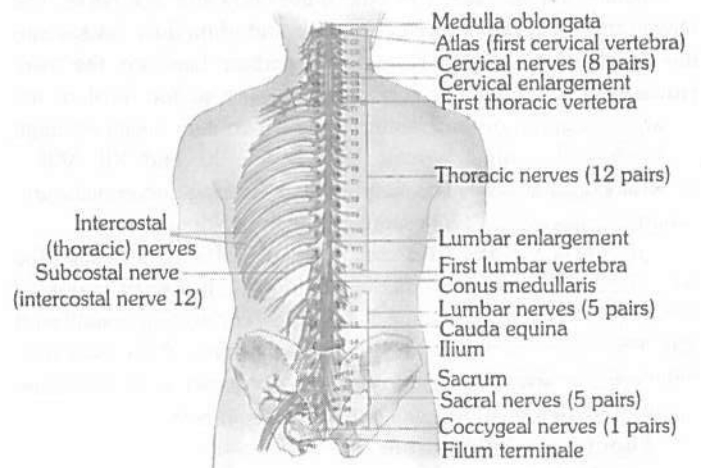


Fig : 5.6-16 External anatomy of the spinal cord and the spinal nerves

The cross section of spinal cord reveals the following structures –

- (1) **Central canal** : In the centre of spinal cord, there is a canal called central canal. It is filled with cerebrospinal fluid. central canal is continuous with 4th ventricle of medulla oblongata.
- (2) **Dorsal fissure** : In the mid dorsal line, there is a groove extending throughout its length.
- (3) **Ventral fissure** : It is also a groove situated in the mid ventral line throughout the length of spinal cord.
- (4) **Dorsal septum** : It is a partition extending from dorsal fissure to central canal.
- (5) **Grey matter** : It lies around the central canal in the form of a butterfly and sub-divided into 3 horns, surrounded by white matter.

- (6) **Dorsal horns** : It is like horn of grey matter on the dorsal side.
- (7) **Ventral horns** : On the ventral side of the grey matter are horn like structures the ventral horns.
- (8) **Lateral horns** : These are horns on the lateral side of grey matter.
- (9) **White matter** : White matter is present around grey matter. Dorsal and ventral horn, divide white matter into 3 broad area on each side –
 - (i) Anterior (ventral) white columns
 - (ii) Posterior (dorsal) white columns
 - (iii) Lateral white columns.

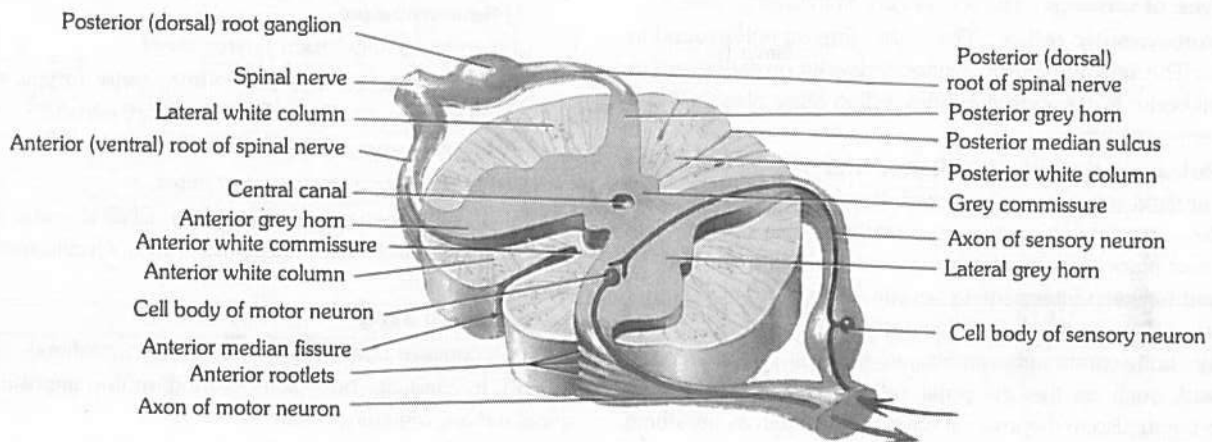


Fig : 5.6-17 T.S. of the thoracic spinal cord of mammal

Reflex action : Reflexes are fast predictable, automatic responses to change the environment. First of all Marshal Hall (1833) studied the reflex action. *Best* and *Taylor* defined reflex action “simplest form of irritability associated with the nervous system is reflex actions or a reflex reaction is an immediate involuntary response to a stimulus.” The reflex actions are involuntary actions because these are not under the conscious control of the brain. Central nervous system is responsible for the control of reflex action.

Reflex arc is formed by the neurons forming the pathway taken by the nerve impulses in reflex action. The simplest reflexes are found in animals involving a single neuron and the following pathway –

Stimulus → Receptor → Neuron → Effector → Response

(1) **Component of reflex action** : The whole of the reflex includes five parts –

(i) **Receptor organs** : Receptors are windows of the body or guards of the body. These are situated on all, important organs, for example – eyes, nose, ear, tongue, integument etc. These perceive the stimuli from outside the body.

(ii) **Sensory neurons** : These are also termed afferent neurons. These carry the stimuli from receptors to spinal cord. These neurons are situated in the ganglion on the dorsal side of spinal cord grey matter or brain stem.

(iii) **Association neurons or Integrating centre** : These are also called intermediate neurons or interstitial neurons. These are found in spinal cord. They transfer the impulses from sensory neurons to motor neurons. Association neurons forms monosynaptic and polysynaptic reflex arc.

(iv) **Motor neurons** : These are situated in the ventral horn of spinal cord. These carry the impulses to effector organs.

(v) **Effector organs** : These are the organs, which react and behave in response to various stimuli, for example – muscles and glands.

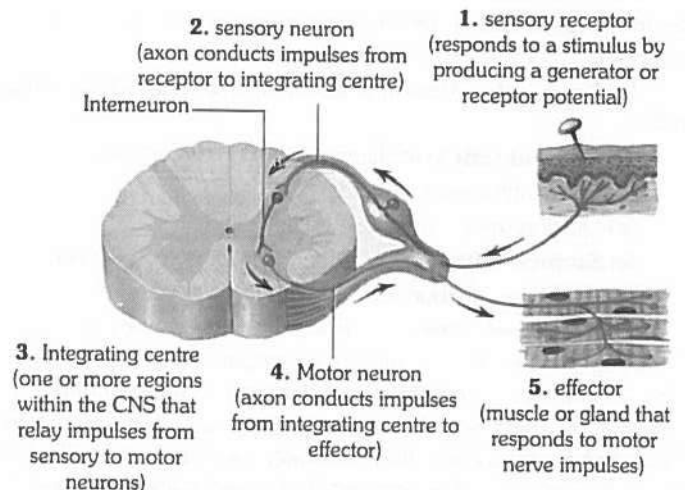


Fig : 5.6-18 General components of a Reflex arc

(2) **Mechanism of reflex action** : The time taken by a reflex action is too short, for example – in frog it is 0.3 metre per second and in man 5-120 metre per second. Whenever, a part of the body is stimulated by any stimulus, for example – pin pricking, then the stimulus is converted into impulse. This impulse is perceived by the dendrites of sensory neurons. From here, the stimulus reaches the spinal cord through axonic fibres. In the spinal cord, this stimulus passes through synaptic junctions and reaches the intermediate neurons, from where this stimulus reaches the effector organs through motor nerve fibres. As soon as the stimulus reaches the effector organs, it is stimulated and that part of the body is immediately withdrawn. The whole reflex action takes place so rapidly and quickly that we know it when it is completed.

(3) **Type of reflexes** : The reflexes are of following types –

(i) **Monosynaptic reflex** : This is the simplest reflex found in vertebrates. The sensory neuron synapses directly on to the motor neuron cell body. In this case the reflex action takes place without the involvement of brain.

(ii) **Polysynaptic spinal reflex** : This has at least two synapses situated within the spinal cord. It involves a third type of neuron also – the internuncial or inter-mediate relay neuron. The synapses take place between the sensory neuron and intermediate neuron, and between intermediate neuron and the motor neuron. These two reflex arcs allow the body to make automatic, involuntary, homeostatic adjustments, to changes in the external environment, such as the iris pupil reflex and balance during locomotion, and also in the internal environment such as breathing rate and blood pressure.

(iii) **Polysynaptic spinal/brain reflexes** : In this case the sensory neuron synapses in the spinal cord with a second sensory neuron, which passes to the brain. The latter sensory neurons are part of the ascending nerve fibre tract and have their origin in preintermediate neuron synapse. The brain is capable of identifying this sensory information and stores it for further use. The motor activity may be initiated by the brain anytime and the impulses are transmitted down the motor neurons in descending nerve fibre tract, to synapse directly with spinal motor neurons in the postintermediate synaptic region.

(iv) **Simple reflex** : Simple reflex is also known as unconditioned reflex. It is inborn, unlearned, reflex to a stimulus. Simple reflex is mostly protective in function. Example of simple reflex are

(a) **Knee jerk** – Tendon of patella tapped, also called patellar reflex.

(b) **Corneal reflex** (blinking reflex) – closing of eyelids.

(c) Rapid withdrawal of hand while burned or pricked.

(d) Quick recovery of balance while falling.

(e) **Scratch reflex** of frog – in pithed frog with acetic acid.

(f) Coughing, sneezing and yawning.

(v) **Acquired reflex** : Acquired reflex is also known as conditioned reflex. It is not inborn, but acquired and dependent on past experience, training and learning. Demonstration of conditioned reflex was first made by Russian physiologist Ivan Petrovitch Pavlov (1846-1936) in hungry dog. Pavlov rang the bell while feeding dog, thus associated the unconditioned response with additional stimulus. Examples of conditioned reflex are

learning of dancing, cycling, swimming, singing,, driving, etc. These actions are under cerebral control during learning.

Peripheral nervous system

It is formed of a number of long, thin, whitish threads called nerves extending between central nervous system and body tissues. Each nerve is formed of bundles of nerve fibres, fasciculi, held together by connective tissue and surrounded by a white fibrous connective tissue sheath called epineurium.

The nerve fibres are classified into two categories on the basis of presence or absence of myelin (white fatty) sheath.

(1) Medullated or Myelinated nerve fibres.

(2) Non-medullated nerve fibres.

On the basis of function, the nerves are of three types

(1) **Sensory nerve**

(i) It contains only sensory nerve fibres.

(ii) It conducts nerve impulses from sense organs to CNS to produce sensation. e.g. Optic nerve, auditory nerve.

(2) **Motor nerve**

(i) It contains only motor nerve fibres.

(ii) It conducts nerve impulses from CNS to some muscles or glands to control their activities. e.g. Oculomotor nerve, hypoglossal nerve.

(3) **Mixed nerve**

(i) It contains both sensory and motor nerve fibres.

(ii) It conducts both sensory and motor impulses. e.g. All spinal nerves, trigeminal nerve.

On the basis of their origin, nerves are of two types

(1) Cranial or cerebral nerves which either arise from or end into brain.

(2) Spinal nerves which arise from spinal cord.

Cranial nerves

(1) 10 pairs of cranial nerves are present in an anamniote (fishes and amphibians).

(2) Number of cranial nerves found in frog is ten pairs (20).

(3) 12 pairs of cranial nerves are present in an amniote (reptiles, birds and mammals).

(4) Number of cranial nerves found in rabbit and man is 12 pairs (24).

(5) The first 10 pairs are common for frog and rabbit. The additional pairs found in rabbit are spinal accessory and hypoglossal.

(6) The smallest cranial nerve is trochlear in human beings, but in all animals smallest cranial nerve is abducens.

(7) The largest cranial nerve is trigeminal in human beings but vagus is largest cranial nerve in all animals.

(8) Vagus supplies the regions other than head.

(9) The sensory cranial nerves are

I Olfactory – Smell

II Optic – Vision

VIII Auditory – Hearing and equilibrium

(10) The motor cranial nerves are : III, IV, VI, XI and XII.

(11) Extraocular muscle nerves are : III, IV and VI.

(12) The mixed cranial nerves are : V, VII, IX and X (4 pairs).

(13) Number of cranial nerves in snake (Amniota) 10 pairs.

Table : 5.6-3 Cranial nerves of mammal at a glance

	Name	Nature	Origin	Distribution	Function
[I]	Olfactory Nerves	Sensory	Olfactory lobe	Sensory epithelium of olfactory sacs	Receive stimuli from the sensory epithelium of olfactory sac and carry them to olfactory lobes
[II]	Optic nerves	Sensory	In retina of eye	Lateral geniculate nuclei of thalamus	Stimulus of light is carried to optic occipital lobe of cerebral cortex.
[III]	Oculomotor nerves	Motor	Crura cerebri (mid brain)	Eye ball muscles like superior rectus, medial rectus, inferior rectus and inferior oblique. except superior oblique muscle and external rectus	Movement of eye lids and eye ball.
[IV]	Trochlear nerves	Motor	From in between the optic lobes and cerebellum	Superior oblique muscle of eye ball	Movement of eye ball
[V]	Trigeminal nerves	Mixed	From the gasserian ganglia situated on the lateral side of pons	—	—
	(i) Ophthalmic nerve	Sensory	“	Skin of lips, upper eye lid, lacrimal, gland	
	(ii) Maxillary	Sensory	“	Upper lip, skin of nose, lower eye lid. Upper teeth.	Carry the stimuli from these organs to brain
	(iii) Mandibular nerve	Mixed	“	Lower lip and skin of jaw	Carry the stimuli from these organs to brain
[VI]	Abducens nerves	Motor	Pons	Eye muscles external rectus	Movement of eye ball
[VII]	Facial nerves	Mixed	Pons	—	—
	(i) Palatinus	Sensory	—	In the roof of mouth cavity	Carry the impulses from roof of mouth cavity
	(ii) Hyomandibular	Motor	—	Muscles of lower jaw, muscles of neck and pinna (external ear)	Carry the impulses from brain muscled of lower jaws, neck and pinna.
	(iii) Chordatympani	Mixed	—	In salivary glands and taste buds	Receives the stimuli from the taste buds and carry the stimulus to salivary gland.
[VIII]	Auditory nerves	Sensory	Medulla, pons	—	—
	(i) Vestibular nerve	“	—	Semicircular canals, saccule, utricle.	Receives impulses from the internal ear and carry to brain for equilibrium
	(ii) Cochlear nerve	“	—	Cochlea	Impulses associate with hearing.
[IX]	Glossopharyngeal nerve	Mixed	In medulla	Taste buds present in tongue and muscles of oesophagus	Secretion of saliva, taste muscle sense (proprioception)
[X]	Vagus nerve	Mixed	Arising from medulla, 9 th and 10 th cranial nerves unites to form vagus nerve but become separate and divide into branches	—	—
	(i) Superior laryngeal nerve	Motor	—	Glottis, trachea, lung muscle	(1) Smooth muscles contraction and relaxation.
	(ii) Recurrent laryngeal nerve	Motor	—	Glottis, trachea, lung muscle.	(2) Secretion of digestive juice. (3) Muscle sense (proprioception) (4) Sensation of visceral organs.
	(iii) Cardiac nerve	Motor	—	Heart Muscles	From brain to heart muscles
	(iv) Pneumogastric	Motor	—	In the abdominal cavity, in stomach and lungs.	Carry impulse from these organs to brain and from brain to muscles of these organs.
	(v) Depresser nerve	Motor	—	Diaphragm	Carry the impulse to diaphragm
[XI]	Spinal accessory	Motor	Medulla	Muscles of neck and shoulders, voluntary muscles of pharynx, larynx, and soft palate.	Swallowing movements, movement of head.
[XII]	Hypoglossal nerve	Motor	Medulla	Muscles of tongue and neck	Movement of tongue during speech, and swallowing, proprioception (Muscle sense).

Spinal nerves : Spinal nerves arise from grey matter of spinal cord. There are 31 pairs of spinal nerves in man (37 pairs in rabbit). All spinal nerves are mixed. The spinal nerves in man are divided into 5 groups.

- (1) Cervical (C) → 8 pairs — in Neck region
 - (2) Thoracic (T) → 12 pairs — in thoracic region
 - (3) Lumbar (L) → 05 pairs — upper part of abdomen
 - (4) Sacral (S) → 05 pairs — lower part of abdomen
 - (5) Coccygeal (CO) → 01 pairs — represent the tail nerves
- Total = 31 pairs

Number of spinal nerves in frog is 10 pairs. In some frog like *Rana tigrina*, 10th pair may be reduced or absent. The first pair of spinal nerves in frog is hypoglossal. The last pair of cranial nerves of mammals has the same name. Brachial plexus is formed by 2nd and 3rd spinal nerves in frog. Sciatic plexus is formed by 7, 8 and 9 spinal nerves in frog. Glands of Swammerdam are calcareous glands found at the places of emerging of spinal nerves in frog.

Spinal nerve formula can be written as – $C_8, T_{12}, L_5, S_5, CO_1$, Spinal nerves exit via intervertebral foramen. Each spinal nerve arises from spinal cord by 2 roots

(1) **Dorsal (= Afferent = Sensory = Posterior) root** is a continuation of dorsal horn and is formed of grey matter. It presents a ganglionic swelling in middle, called dorsal root ganglion. These transmit sensory nerve impulses from the sense organs to spinal cord (touch, pain, temperature). They activate involuntary reflexes.

(2) **Ventral (= Efferent = Motor) root** are continuation of ventral horn and is also formed of grey matter. No ganglion are present. It is formed of only efferent nerve fibers. They transmit motor nerve impulses to effector organs e.g., glands and muscles. Each spinal nerve has 4 branches –

(i) **Ramus dorsalis :** Supplies to skin and muscles of dorsal side.

(ii) **Ramus ventralis :** Supplies to skin and muscles of ventral and lateral sides and also to upper and lower limbs. Ventral root of certain spinal nerve form 5 nerve plexi on either side, i.e., cervical, thoracic, lumbar, sacral, caudal.

(iii) **Ramus communicans :** It joins sympathetic ganglion of autonomic nervous system.

(iv) **Meningeal branch :** Vertebra, vertebral blood vessel.

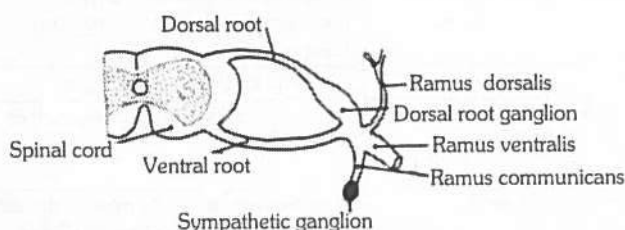


Fig : 5.6–19 Origin and distribution of spinal nerve

Autonomic nervous system

Autonomic nervous system was discovered by Langley. Autonomic nervous system (ANS) automatically regulates the activities of smooth muscles, cardiac muscles and glands. This co-ordination is involuntary. Autonomic nervous system usually operates without conscious control. Autonomic nervous system is entirely motor. All autonomic axons are efferent fibres. Autonomic nervous system is regulated by centres in brain like cerebral cortex, hypothalamus and medulla oblongata. Autonomic fibres release chemical transmitters at synapse. On the basis of the transmitter produced, these fibres may be classified as cholinergic or adrenergic. Cholinergic fibres release acetylcholine. Adrenergic fibres produce norepinephrine (noradrenaline), also called sympathetin.

Nature of autonomic control : The autonomic nervous system regulates and co-ordinates such vital involuntary activities like heart beat, breathing, maintenance of the composition of body fluids (= homeostasis) and body temperature, gut peristalsis, secretion of glands, etc. Autonomic nervous system consists of two divisions –

(1) **Sympathetic ANS** (Thoracolumbar out flow)

- (i) Thoraco Lumbar out flow (all thoracic + 3 lumbar)
- (ii) Preganglionic nerve small.
- (iii) Post ganglionic nerve long.
- (iv) Preganglionic nerve secrete acetyl choline.
- (v) Postganglionic nerve secrete **sympathetin**. (*nor-epinephrine*)
- (vi) It shows sympathy (generally increase the function).
- (vii) Expenditure of energy takes place.
- (viii) It increase defence system of body against adverse condition.
- (ix) It is active in stress condition, pain, fear and anger.

(2) **Parasympathetic ANS** (Cranio-sacral out flow)

- (i) ANS Cranio sacral outflow (cranial-III, VII, IX, X Nerves)- (sacral-II, III, IV Nerves)
- (ii) Preganglionic nerve long.
- (iii) Postganglionic nerve small.
- (iv) Secrete acetyl choline only.
- (v) It provide relaxation, comfort, pleasure, at the time of rest.
- (vi) Restoration and conservation of energy takes place.
- (vii) Collateral ganglia present in sympathetic nervous system.
- (viii) **Horner's syndrome** results from the damage of sympathetic trunk of one side.
- (ix) A patient of Horner's syndrome exhibits lack of sweating (on affected side), sunken eyes and constricted pupil.

Table : 5.6-4 Difference between sympathetic and Parasympathetic

S.No.	Name	Sympathetic	Parasympathetic
1.	Secretion	Acetyl choline and Sympathetin	Acetyl choline only
2.	Blood pressure	Increase	Decrease
3.	Blood vessel to skin	Constrict	Dilate
4.	Blood vessel to heart	Dilate	Constrict
5.	Blood vessel to lung and muscle	Dilate	Constrict
6.	Pupil	Dilate	Constrict
7.	Lacrimal gland	Stimulate	Inhibits
8.	Heart beat	Increase	Decrease
9.	Adrenal secretion	Stimulate	Inhibit
10.	Breathing and BMR	Increase	Decrease
11.	Nostrils	Dilate	Constrict
12.	Urinary bladder	Relax	Constrict
13.	Iris	Constrict	Dilate
14.	Salivary gland	Decrease	Increase
15.	Digestive gland	Decrease	Increase
16.	Gut peristalsis	Decrease	Increase
17.	Ejaculation	Increase	Decrease
18.	Bile	Decrease	Increase
19.	Renin (kidney)	Increase	Decrease
20.	Bronchi	Dilate	Constrict

Cutting of sympathetic or parasympathetic nerve to heart will not stop functioning of heart. Heart will beat but without any nervous control. Autonomic nervous system functions rapidly to alter visceral functions (3-5 seconds). It is activated mainly by centres located in spinal cord, brain stem and hypothalamus. Limbic cortex also influences its function often this system function via visceral reflexes *i.e.* sensory signal → enter autonomic ganglia → spinal cord → brain stem → or hypothalamus can elicit reflex responses back to visceral organs to control their activities.

Biochemical Aspect of Nervous Physiology

Nerve cells (= neurons) : Irritability is a basic characteristic of the "living substance", *i.e.*, the protoplasm. Consequently, every living cell becomes excited when stimulated. However, the nerve cells and muscle fibres are specialized excitable cells of body, capable of transmitting or conducting excitations along their membranes. Of these, muscle cells are further specialized for contraction while nerve cells are further specialized for receiving stimuli (as sensory or receptor cells) and transferring excitations from one to the other.

A typical neuron consists of a nucleated cell body (= cyton, soma or perikaryon), five to seven short, slender and branched (= arborized) dendrites, and a single, relatively thicker and longer fibrous axon. The latter is terminally branched into short telodendria. Each telodendron bears a terminal **knob** or **button**. Buttons of one neuron lie upon dendrites or cytons of adjacent neurons (figure), or upon muscle fibres or glands.

Nerve fibres : Although, all parts of a neuron transmit excitations (= impulses), but the transmission is always unidirectional. The dendrites and cytons usually constitute the impulse receiving parts which receive impulses directly from receptors, or from other adjacent neurons. The axons are specialized as fibres conducting impulses away from the receiving parts. Thus, the reaction or response impulses are always carried to the effectors by axons. That is why, the term '**nerve fibres**' is usually applied to the axons. The latter are 0.1 mm to one or more (upto 10) metres long and about 0.025 m thick on an average.

Main properties of nervous tissue : The nervous tissue has two outstanding properties excitability and conductivity.

(1) **Excitability** : It is the ability of the nerve cells and fibres to enter into an active state called the **state of excitation** in response to a stimulus. Excitation arises at the receptors on account of various stimuli such as light, temperature, chemical, electrical or pressure which constantly act on the organisms.

(2) **Conductivity** : The excitation does not remain at the site of its origin. It is transmitted along nerve fibres. The transmission of excitation in a particular direction is called conductivity.

Definition of nerve impulse : A wave of reversed polarity or depolarization (action potential) moving down an axon is called a nerve impulse.

Mechanism of conduction of nerve impulse

Most accepted mechanism of nerve impulse conduction is ionic theory proposed by Hodgkin and Huxley. This theory states that nerve impulse is an electro-chemical even governed by differential permeability of neurilemma to Na^+ and K^+ which in turn is regulated by the electric field.

(1) **Transmission of nerve impulse along the nerve fibre**

(i) **Polarization (Resting membrane potential-RMP)** : In a resting nerve fibre (a nerve fibre that is not conducting an impulse), sodium ions (Na^+) predominate in the extracellular fluid, whereas potassium ions (K^+) predominate in the intracellular fluid (within the fibre). Intracellular fluid also contains large number of negatively charged (anions) protein molecules. Na^+ are 10 times more outside the neuron and K^+ ions are 25 times more inside the cell. Thus it makes a considerable difference between the ion concentration outside and inside the plasma membrane. It also causes a difference in electrical charges on either side of the membrane. The plasma membrane is electrically positive outside and negative inside. This difference is called potential difference. The potential difference across the plasma membrane is known as resting potential. This potential averages - 70 mv (- 40 to - 90 mv) in inner side of membrane in respect to outer side.

A higher concentration of cations outside the membrane compared to the concentration of cations inside it. This state of the resting membrane is called polarised state and makes its inner side electronegative to its outside.

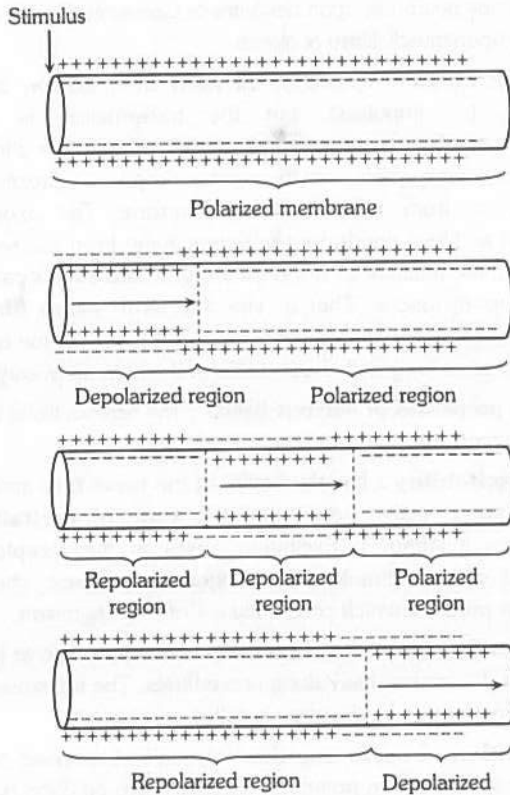


Fig : 5.6-20 Transmission of nerve impulse

(ii) **Depolarization (Action membrane potential or AMP)** : When the nerve fibre is stimulated mechanically, electrically, thermally or chemically a disturbance is felt at the point of stimulation which gives rise to a local excitatory state. The membrane becomes permeable to sodium ions. The membrane is negatively charged on the outside and positively charged on the inside. The membrane with reversed polarity is said to be depolarized. This wave of depolarization travelling down a nerve fibre is called **action potential**. Infact, the action potential “moves” in the manner of a spark moving along a fuse. This “moving” action potential constitutes the **nerve impulse**. The action potential (impulse) is the basic means of communication within the nervous system. The action potential of + 45 mv on inner side of axolemma in respect to its outer side is also called spike potential.

(iii) **Repolarization** : With the increase of sodium ions inside the nerve cell, the membrane becomes less permeable to sodium ions whereas the permeability of the membrane to potassium ions increases. The sodium ions are pumped out of the cell and potassium ions are pumped into the cell until the original resting state of ionic concentration is achieved. Thus this makes the membrane negative on inside and positive on outside. This process is called repolarization.

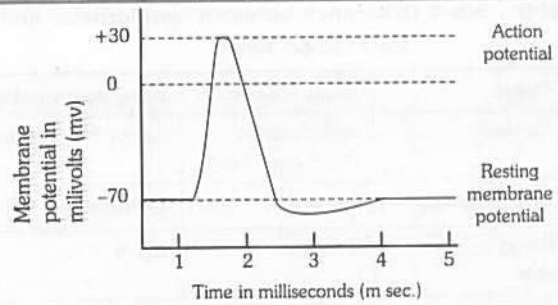


Fig : 5.6-21 Record of potential changes

The last movement of ions is thought to take place by an active transport mechanism called sodium potassium pump (also called sodium potassium exchange pump or sodium pump). The sodium-potassium pump is a process of expelling out sodium ions and drawing in potassium ions against concentration and electrochemical gradient. The entire process of repolarization requires some time during which the nerve cannot be stimulated again. This period is called **refractory period**. During repolarization, as the cell returns to its resting potential, the neuron is ready to receive another stimulus.

The synapse : The synapse is an area of functional contact between one neuron and another for the purpose of transferring information. Synapses are usually found between the fine terminal branches of the axon of one neuron and the dendrites or cell body of another. This type of neuron is called axo-dendrite synapse. Sir Charles Sherrington (1861-1954) was the first person who used the term ‘synapse’ to the junctional points between two neurons.

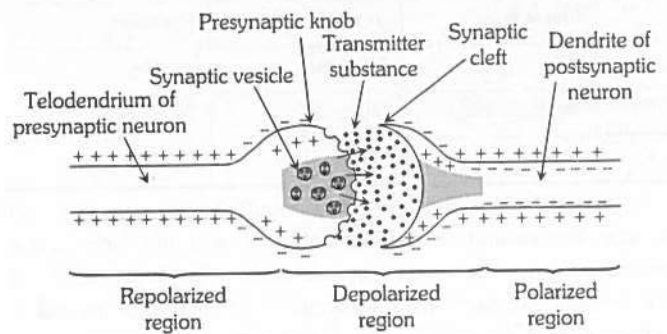


Fig : 5.6-22 Impulse conduction at synapse

(1) **Structure of synapse** : A typical (generalized) synapse consists of a bulbous expansion of a nerve terminal called a pre-synaptic knob lying close to the membrane of a dendrite. The cytoplasm of the synaptic knob contains mitochondria, smooth endoplasmic reticulum, microfilaments and numerous synaptic vesicles. Each vesicle contains neurotransmitter (chemical substance) responsible for the transmission of the nerve impulse across the synapse. The membrane of the synaptic knob nearest the synapse is thickened and forms the presynaptic membrane. The membrane of the dendrite is also thickened and is called the post synaptic membrane. These membranes are separated by a gap, the synaptic cleft. It is about 200 Å across. The post synaptic membrane contains large protein molecules which act as receptor sites for neurotransmitter and numerous channels and pores.

The two main neurotransmitters in vertebrate nervous system are acetylcholine (ACh) and noradrenaline although other neurotransmitters also exist. Acetylcholine (ACh) was the first neurotransmitter to be isolated and obtained by Otto Loewi in 1920 from the endings of parasympathetic neurons of the vagus nerve in frog heart. Neurons releasing acetylcholine are described as cholinergic neurons and those releasing noradrenaline are described as adrenergic neurons.

(2) Mechanism of transmission of nerve impulse at a synapse : The process of chemical transmission across synapses was discovered by Henry Dale (1936). The physiological importance of synapse for the transmission of nerve impulses was established by McLennan in 1963. A brief description of the mechanism of synaptic transmission is given below

(i) When an impulse arrives at a presynaptic knob, calcium ions from the synaptic cleft enter the cytoplasm of the presynaptic knob.

(ii) The calcium ions cause the movement of the synaptic vesicles to the surface of the knob. The synaptic vesicles are fused with the presynaptic membrane and get ruptured (exocytosis) to discharge their contents (neurotransmitter) into the synaptic cleft.

(iii) The synaptic vesicles then return to the cytoplasm of the synaptic knob where they are refilled with neurotransmitter.

(iv) The neurotransmitter of the synaptic cleft binds with protein receptor molecules on the post synaptic membrane. This binding action changes the membrane potential of the postsynaptic membrane, opening channels in the membrane and allowing sodium ions to enter the cell. This causes the depolarization and generation of action potential in the post-synaptic membrane. Thus the impulse is transferred to the next neuron.

(v) Having produced a change in the permeability of the postsynaptic membrane the neurotransmitter is immediately lost from the synaptic cleft. In the case of cholinergic synapses, acetylcholine (ACh) is hydrolysed by an enzyme acetylcholinesterase (AChE) which is present in high concentration at the synapse.

(vi) The products of the hydrolysis are acetate and choline which are reabsorbed into the synaptic knob where they are resynthesized into acetylcholine, using energy from ATP.

Table : 5.6-5 Types and Nature of Neurotransmitters

S.No.	Excitatory	Inhibitory
1.	Acetylcholine	Gamma amino butyric acid (GABA)
2.	Norepinephrine (NE)	Glycine
3.	Serotonin	
4.	5-hydroxy tryptamine (5-HT)	
5.	Dopamine	
6.	Histamine	
7.	Glutamate	
8.	Epinephrin	
9.	Gastrin	
10.	Glucagon	
11.	Melatonin	
12.	ADH	

(3) Neurotransmitters : As explained in the discussion of synapses, neurotransmitters are chemicals released from a presynaptic neuron that interact with specific receptor sites of a postsynaptic neuron. At least sixty chemicals thought to have the capacity to act as neurotransmitters have been discovered.

Synapse, A one-way valve : The synapse cannot transmit an impulse in the reverse direction as the dendrites cannot secrete a neurotransmitter. Thus, the synapse acts as a one-way valve, allowing the conduct of impulse from axon to dendron only.

Synaptic delay : Transmission of an impulse across a synapse is slower than its conduction along a neuron. This is because of the time needed for the release of a neurotransmitter, its diffusion through the synaptic cleft, and its action on the postsynaptic membrane. The difference in the rate is called synaptic delay. It amounts to about half a millisecond at body temperature (37°C).

Synaptic fatigue : It is a temporary suspension of impulse transmission in the region of synapse due to exhaustion of its neurotransmitter. It lasts for several seconds during which the neurotransmitter is resynthesized. Synaptic fatigue is the only fatigue that affects the nervous tissue. Conduction of the nerve impulse along the neurons is not subject to fatigue.

“All or None law” (Keith Lucas, 1905) : When stimulated, the axon membrane (= axolemma) does not respond for a moment due to its resistance or threshold to stimulation. However, when its threshold is broken, the stimulation is conducted through its whole length as a strong impulse. If the stimulation is too weak to break the axon’s threshold, impulse is not established, but if the intensity of stimulation is much more than the threshold value, impulse conduction remains normal. Thus, the action potential obeys “all or none law”. In other words, impulse conduction is such a triggered phenomenon which, though occurs in a twinkling, like an explosion, but only when it reaches “ignition point” or firing level”.

Sense Organs

How are environmental changes detected ? In its broadest context, sensation is the conscious or unconscious awareness of external or internal stimuli. Cells which are specialised to receive stimulation are called receptors.

The sensory system consists of simple to complex structures called sensory receptors. An animal responds to a stimulus in a four-step process – sensory transduction, transmission, integration and response.

Types of receptors

(1) **Exteroreceptors :** Receive stimulation directly from external environment. These may be of following type

(i) **Photoreceptor :** Sensitive to light (Eye)

(ii) **Thigmoreceptor :** Sensitive to touch.

(iii) **Tectoreceptor :** Sensitive to touch.

(iv) **Tangoreceptor :** Sensitive to touch pressure.

(v) **Phonoreceptor :** Sensitive to sound (Ear).

- (vi) **Olfactoreceptor** : Sensitive for smell (Nose).
- (vii) **Gustoreceptor** : Sensitive to taste (Tongue).
- (viii) **Thermoreceptor** : Sensitive to temperature.
- (ix) **Calo receptor** : Sensitive to heat.
- (x) **Frigido receptor** : Sensitive to cold.
- (xi) **Galvano receptor** : Sensitive to electric current.
- (xii) **Rheoreceptor** : Sensitive to water or air current.
- (xiii) **Geo receptor** : Sensitive to gravity.
- (xiv) **Telereceptor** : Sensitive to distance. (Receptors of vision, hearing and smell receive stimuli from a distance hence called telereceptor).

(2) **Proprioceptors** : Proprioceptors are located in skeletal muscles, joints, tendons etc. It is from these receptors that we know the position of our arm or leg without having to look at it.

(3) **Intero receptor** : These are present in internal organ. Ex. receptor for hunger, thirst, pain and balancing.

Few important receptors

(1) Important tangoreceptor

- (i) **Merckel's corpuscles** : Found in epidermis (stratum malpighi) of skin.
- (ii) **Merckel's disk** : Found in epidermis (stratum malpighi) of skin.
- (iii) **Meissner's corpuscles** : Present in skin around the base of hair and feather. These are sensitive for touch and pressure both.
- (iv) **Genital corpuscles** : These are sensitive cells with nerve endings in skin around the genital organ.
- (v) **Grandey's corpuscles** : Found in birds at the base of the beak. These are kidney shaped in structure.
- (vi) **Herbert corpuscles** : Found in buccal cavity of birds.
- (vii) **Capsulated corpuscles** : These are sensitive cells encapsulated and found in skin.
- (viii) **Pacinian corpuscles** : Found in deep layer of dermis and sensitive to pressure.
- (ix) **Golgi corpuscles and Mazzoni corpuscles** : These are sensitive to touch and found in subcutaneous region.

(2) Important Olfactoreceptor

Jacobson's organ (Vomero-nasal organ) : It is concerned with smell. These were 1st appear in amphibians and well developed in snake, lizzard and sphenodon that is reptile. These are less developed in birds and mammal. Structure is blind sac like and lined by olfactory epithelium (Shneiderian membrane). Jacobsons organ is not found in rabbit. In man it is vestigeal organ. In human foetus Jacobson organ present. Jacobson organ also found in marsupiales, Rodents, and Insectivora.

(3) Important Thermoreceptor

(i) **Krause end bulb** : These are sensitive for temperature and pain and frigido in nature. Found in lips, tongue, conjunctiva of eyes and corium of finger.

(ii) **Organ of Ruffini** : Sensitive to temperature and mainly related with heat.

(iii) **Ampulla of Lorenzini** : Found in snout region of cartilagenous fishes these are helpful in detecting the temperature of water.

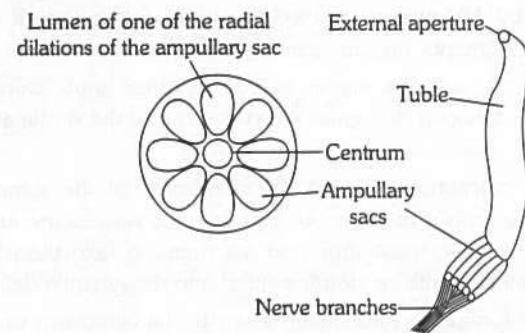


Fig : 5.6-23 Ampulla of Lorenzini

Eye

Human have binocular vision. The eye can discriminate colour, appraise length, width and depth visually and form true inverted image.

Structure of eye

The eyes are two in number and lodged in orbits (bony socket) of skull. The eye is a hollow, spherical organ, about 2.5 cm in diameter and about 6 to 8 gram in weight. It has two parts –

(1) **Protective devices** : Eye has four protective devices.

(i) **Eye brows** : The outwardly directed hair of the eyebrows carry the sweat and rain drops trickling down the forehead to the sides to prevent their falling into the eyes.

(ii) **Eye lids (Palpebrae)** : In man two eyelids are present, upper is movable. They are regularly closed at short intervals to clean the cornea. This is called blinking. In frog out of two upper eyelid is immovable and lower eyelid is movable. Nictitating membrane is present in frog which protect eye in water. Movement of nictitating membrane takes place by retractor bulbi. It becomes folded by levator bulbi.

A nonfunctional vestigeal nictitating membrane, called plica semilunaris, occurs in human eyes. It remains permanently retracted at the inner angle of each eye.

(iii) **Eye lashes** : The eyelids bear at the free edge a row of stiff hair, the eye lashes. These check the entry of dust particles, tiny insects and rain drops into the eyes.

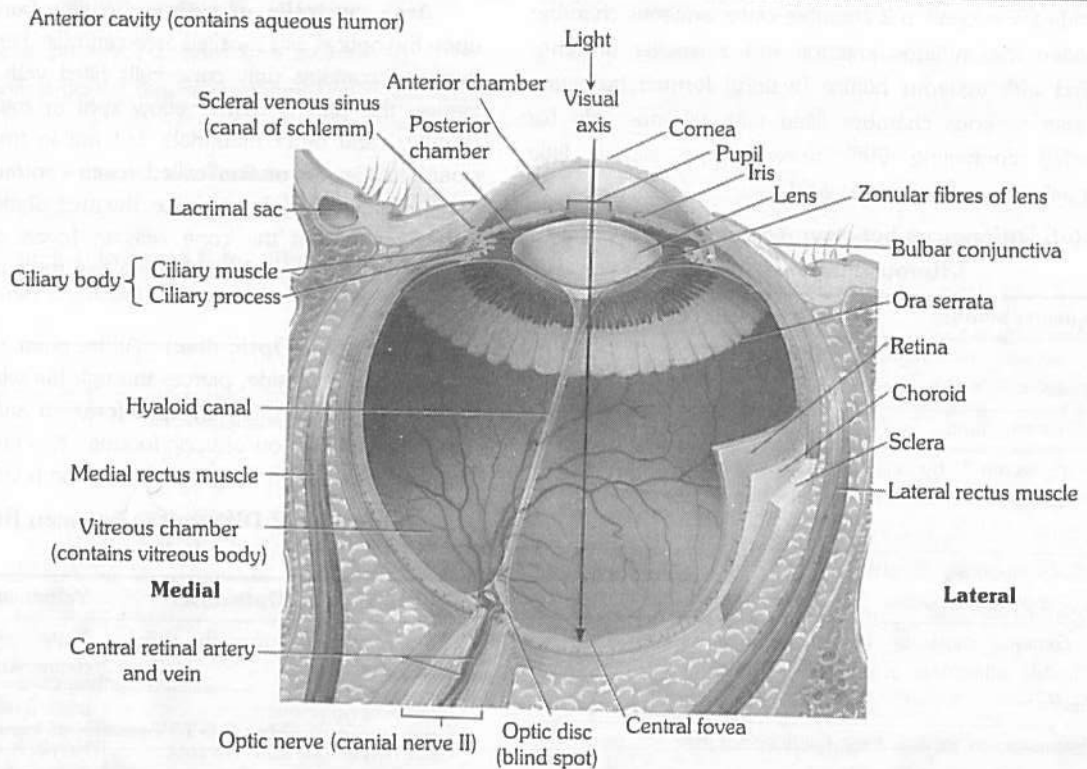


Fig : 5.6-24 Superior view of transverse section of right eyeball

(iv) **Eye glands**

(a) **Meibomian gland** : The eye-lids bear at the free edge a row of meibomian gland that is modified sebaceous gland. (Act as a lubricant).

(b) **Lacrimal gland or Tear gland** : It lies in the upper outer part of the orbit and secretes a slightly saline, watery fluid that contains a bacteriolytic enzyme named lysozyme. This secretion moistens the surface of the eyeball. The excess of this secretion passes through nasolacrimal duct. It is modified sweat gland.

(c) **Harderian gland** : Some aquatic mammals (whale) possess harderian gland which lubricate nictitating membrane. It is also found in frog and birds.

(d) **Glands of zeis (zis)** : These are modified sebaceous gland, found at base of hair follicle of eye lashes, pour lubricating fluid in hair follicle. Infection of these glands is Sty.

(e) **Glands of Moll** : It is modified sweat gland and open into the follicles of eyelashes.

In human meibomian, lacrimal, Moll's glands, and zeis glands are present.

(v) **Connective tissue** : A layer of fatty connective tissue surrounds the eyeball. It serves as a soft shockproof pad.

(2) **Eyeball** : Eyeball is made up of 3 coats or tunic.

(i) **Sclerotic layer (Fibrous tunica)** : Outer most and opaque, fibrous and non-vascular layer easily seen as white of the eye. It is a coat of dense connective tissue made up of collagen fibres and fibroblasts. Sclera covers entire eyeball except cornea, gives shape to eyeball. Sclera in frog is cartilaginous.

(a) **Cornea** : In the centre, sclerotic layer it merges with the transparent round window called cornea.

(b) **Conjunctiva** : The cornea and exposed part of sclera are covered externally by a thin, transparent membrane the conjunctiva.

(ii) **Choroid layer (Vascular tunica)** : Also known as uvea middle. It is vascular layer which supplies nutrients to the eye. It is distinguished into three parts choroid, ciliary body and iris.

(a) **Choroid** : It is highly vascular posterior portion of vascular tunic. The choroid occurs in the main part of eyeball adhered to the sclerotic. (The pigment is reddish in rabbit and black, brown or bluish in man).

(b) **Ciliary body** : Ciliary body is vascular and pigmented like choroid, made up of ciliary processes and ciliary muscles (only circular type). The ciliary body is hidden by iris. The ciliary body helps in accommodation by altering the focus of eye from object or the shape of lens near or far vision.

(c) **Iris** : Beyond the ciliary body, the vascular tunic sharply turns inwards, forming a circular, shelf-like diaphragm called iris. The colour of the iris is responsible for colour of eye e.g., brown, black, blue or green. In albinos, iris is deficient of pigments.

Lens : Lens is colourless, transparent and fibrous crystalline structure made up of protein (α and β crystalline protein) and enclosed in lens membrane. It is ectodermal in origin. Lens is lodged in eyeball by suspensory ligament of ciliary body. Suspensory ligaments are known as "Zonula of Zinn". In man lens is biconvex while in frog it is elliptical (subspherical).

Lens divide the eyeball in 2 chamber outer aqueous chamber (partially divided into a large anterior and a smaller posterior chamber) filled with aqueous humor (watery) formed by ciliary body and inner vitreous chamber filled with vitreous jelly (or Wharton's jelly) containing 99% water, some salt a little mucoprotein (vitrein) and hyaluronic acid.

Table : 5.6-6 Differences between Aqueous humour and Vitreous humour

S.No.	Aqueous humour	Vitreous humour
1.	It occurs in aqueous chambers.	It occurs in vitreous chamber.
2.	It is a watery fluid	It is a jelly-like substance.
3.	It is secreted by ciliary processes.	It is apparently secreted by retina during development of eye.
4.	It is continuously absorbed into blood and replaced.	It is not absorbed or replaced
5.	It contains most of the diffusible substances of the plasma	It consists of water (99%) protein vitrein, hyaluronic acid and collagen fibres.
6.	Obstruction in its flow may damage retina by increasing intraocular pressure.	It does not flow.
7.	Refractive index is 1.33 D	1.34 D

(iii) **Retina (Neurosensory tunica)** : It is innermost, thin and transparent, purplish red due to the presence of the eye pigment rhodopsin (in rods) or visual purple which was extracted by Kuhne (1876) and named 'Schpurpur' (Visual purple). Made up of 4 distinct layer –

- Cuboidal pigmented epithelium (towards choroid).
- Layer of rods and cones.
- Layer of bipolar neurons.
- Layer of ganglia (Towards vitreous chamber innermost).

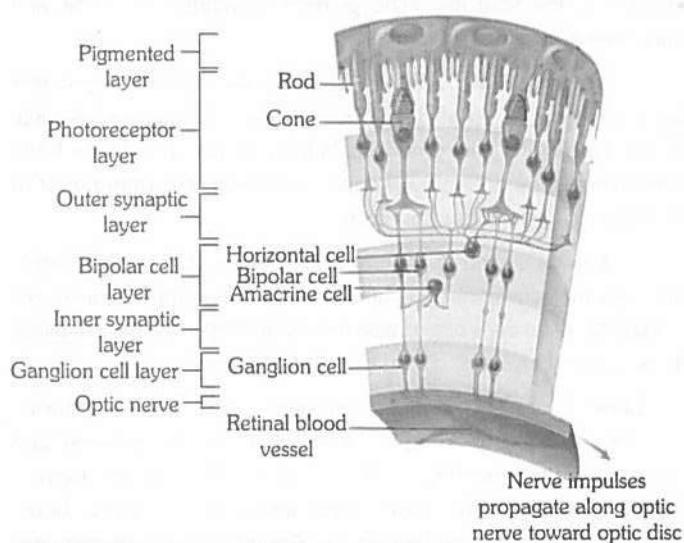


Fig : 5.6-25 Microscopic structure of the retina

Area centralis of retina : A little part of retina that lies upon the optical axis is called area centralis. Here, the retina is very thin and contains only cone cells filled with a yellow pigment. Hence, this part is called yellow spot or macula lutea. In man (Rabbits) and other mammals, but not in frogs, this area has a small shallow depression called fovea centralis. The later is the most sensitive part of an eye, i.e. the area of most acute vision. It is also claimed that the cone cells in fovea centralis are placed somewhat obliquely. So that these can form magnified images of object.

Blind spot (Optic disc) : At this point, the optic nerve turns towards the outer side, pierces through the whole thickness of the wall of eyeball, forming an optic foramen and runs to the brain. Obviously, the region of optic foramen has no retina. It therefore, does not take part in image formation and is called blind spot.

Table : 5.6-7 Differences between Blind spot and Yellow spot

Blind spot (Optic disc)	Yellow spot (Macula lutea)
It lies a little away from the yellow spot.	It lies exactly opposite the centre of the cornea.
It contains no pigment.	It has a yellow pigment.
Optic nerve starts from this spot.	No nerve starts from this spot.
It lacks a depression.	It has a shallow depression, the fovea centralis, at its middle.
It lacks visual receptors and is insensitive to light.	It has visual receptors and is sensitive to light.
The eye coats are absent at blind spot.	Eye coats are present at yellow spot.
No image is formed at this place.	Image is formed at this place.

Ora seratta : The functional retina terminates anteriorly along an irregular border, the ora seratta.

Table : 5.6-8 Function of the parts of human eye

Part	Function	Part	Function
Lens	Refracts and focuses light.	Ciliary body	Holds lens in place.
Iris	Regulates light entrance.	Retina	Contains receptors.
Pupil	Admits light.	Rods	Allow black and white vision
Choroid	Absorbs extra light.	Cones	Allow colour vision.
Sclera	Protects	Optic nerve	Transmits impulse.
Cornea	Refracts light.	Fovea centralis	Region of cones in retina
Humours	Refracts light.		

Working of eye

(i) **Mechanism of light perception** : The human eye has two functional parts – Dioptic or Focussing part and Receptor part.

(ii) **Focussing part** : It consists of conjunctiva, cornea, aqueous humour, lens and vitreous humour. These part are transparent and act as lenses. They refract the light rays passing through the eye to bring them to a focus on the retina. Maximum refraction is caused by the cornea, which places the image approximately on the retina. The lens effects fine adjustment and brings the image into a sharp focus.

(iii) **Receptor part** : It comprises the retina. The image formed on the retina is inverted and smaller. It converts the energy of specific wave lengths of light into action potential in nerve fibre.

(a) **Pathway of sensory impulses from eye to brain** : The nerve impulses generated in the retina of the eye in response to light follow a definitive path and terminates in visual cortex in each optic lobe which act as primary visual center.

Biochemistry of eye

The receptor cells of eye are called photoreceptor or visual cells. They are of two types – Rod cells and Cone

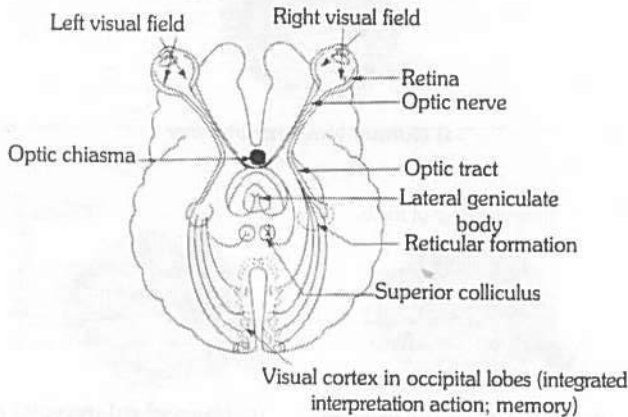


Fig : 5.6-26 Pathway of sensory impulses from eye to brain

(1) **Rod cells** : The rod cells contain a purplish pigment called visual purple or rhodopsin. They function in dim light and at night. They produce poorly defined images. Bright light splits rhodopsin into a lipoprotein scotopsin and a carotenoid pigment retinal (retinine) a process called bleaching. The splitting of rhodopsin depolarizes the rod cell and it releases a neurotransmitter, passing the nerve impulse via bipolar neuron and ganglion cells to the optic nerve. In the dark, rhodopsin is resynthesized from scotopsin and retinal. This process is called 'dark adaptation'. It makes the rods functional. It takes sometime for rhodopsin to be reformed. This is why on entering a dark room at daytime or on coming out of a well lighted room at night we feel blind for a while, when we go from darkness into bright light, we feel difficulty in seeing properly for a moment till rhodopsin is bleached and cones become functional.

(2) **Cone cells** : Cones contain iodopsin which is visual violet and made up of photopsin + retinal. The 3 types of cones are erythrolabe (775 nm sensitive to red), cyanolabe (430 nm sensitive to blue) and chlorolabe (sensitive to green 535 nm). However, if all the cone, types are simultaneously stimulated by equal amounts of coloured light than sensation for white light is perceived.

Diurnal animals are adapted to see during day light (Photopic vision) and can perceive colour. In dark, colours are not perceived. Such animals have more cones in their eye than rods.

Table : 5.6-9 Differences between Rod cells and Cone cells

Rod cells	Cone cells
Rods secreted by rod cells.	Cones secreted by cone cells
Produce "Rhodopsin" which is visual purple and made up of scotopsin + 11 cis retinal.	Produce "Iodopsin" which is visual violet and made up of photopsin + 11 cis retinal.
Vitamin-A is needed for the formation of Rhodopsin.	
Rhodopsin is very sensitive to light.	It is sensitive to colour.
Rods are active in dim light or low intensity light.	Cones are active in bright light which is called photopic vision.
Rod cells are absent in fovea centralis of retina.	In fovea centralis only cone cells are present.
Rods are more in number in peripheral region of retina.	Cones are more in number in central region of retina.
Rods are more in nocturnal animals.	Cones are more in diurnal animals.
In owl only rods are present and cones are absent.	In fowls only cones are present and rods are absent.
120 million rods in human.	6 million cones in human.

Accommodation and types of vision

(1) **Accommodation** : Light passes through many refractive surfaces before it is focussed on the retina forming an inverted and true image. The main sites of refraction are cornea → aqueous humor – iris – lens (position can be altered by ciliary body : accommodation) – posterior chamber (= vitreous humor) → retina (in fovea). The refractive index of the eye varies from 59 diopter (when the lens is at rest) to about 71 diopter (when lens is bulging in maximum accommodation). The accommodation reflex occurs when the eye changes its focus from a far away object to nearer one. The change in strength of the lens provides the physiological basis of accommodation. Radial and circular muscle fibres of ciliary muscles play an important role in this as they contract reflexively (parasympathetic control) and increase lens strength. The pupil constricts. This facilitates increase in sharpness of image. Ageing causes loss of accommodation.

Table : 5.6-10 Relationship between structures during accommodation

Object	Ciliary muscle	Suspensory ligament	Lens	Refraction
Near	Contracted	No tension (Relaxed)	Thick	Increased
Distant	Relaxed	Tension maximum	Thin	Decreased

(2) Types of vision

(i) **Binocular vision** : Man has binocular vision in which both the eyes are focussed on the same object but from slightly different angles. The visual fields of both eyes overlap and the foveae of both are focused on the same object. This provides depth to the images, i.e., gives stereoscopic or 3D effect and enables man to judge distances correctly.

(ii) **Vision in other animals** : Primates and predatory animals, such as owl and cat, have binocular vision. In some animals, such as rabbit, birds, each eye is focussed on a separate object. This is termed monocular vision.

(iii) **Colour vision** : It is the ability of some animals to detect colours in an object. Humans, apes, monkeys, and most fishes, amphibians, reptiles and birds have strong colour vision. The insects and crayfish also have colour vision. In vertebrates, colour vision results from the activity of cone cells. Most domestic and nocturnal mammals and sharks lack colour vision. They probably see objects in shades of grey (monochrome vision).

(iv) **Nocturnal and Diurnal vision** : Man has both day vision and night vision as he has both rods and cones in considerable numbers in the retina. Most birds have only day vision as their retina contains mainly cones. Owls have much better night vision than day vision for they possess a large number of rods and few cones in their retina.

Range of vision : The visible range of spectrum varies in animals. Bees, ants, spiders and goldfish can see ultraviolet light, which is invisible to man.

Table : 5.6-11 Correspondence between Camera and Eye

S.No.	Camera	Eye
1.	Box	Sclera
2.	Black inner paint	Choroid
3.	Shutter	Eyelids
4.	Diaphragm	Iris
5.	Light hole	Pupil
6.	Lens	Lens
7.	Light-sensitive plate or film	Retina
8.	Image small and inverted	Image small and inverted

Eye movement

In eye orbit eyeball remain attached with 6 extrinsic muscles.

Out of six, first four are rectus and last two are oblique muscles.

- (1) Anterior rectus or Internal rectus
- (2) Posterior rectus or External rectus
- (3) Inferior rectus
- (4) Superior rectus
- (5) Inferior oblique muscle
- (6) Superior oblique muscle

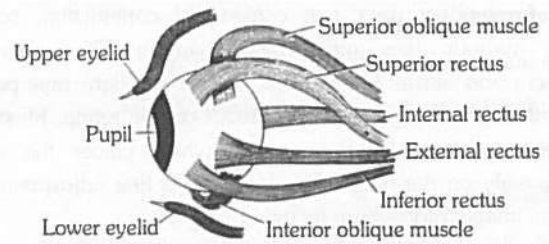
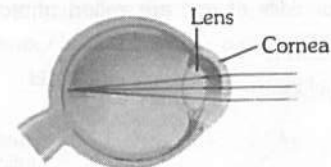


Fig : 5.6-27 Extrinsic muscles of eyeball

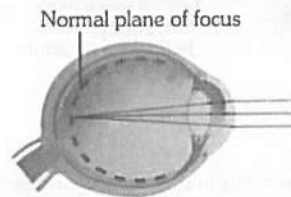
Eye defects

(1) **Myopia (Short or Near-sightedness)**

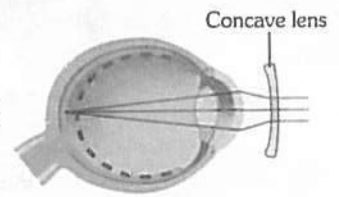
- (i) Near object is clear. Far object is not clear.
- (ii) Eyeball become longer.
- (iii) Image is formed before retina. Can be removed by concave lens.



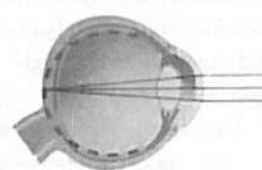
(a) Normal (emmetropic) eye



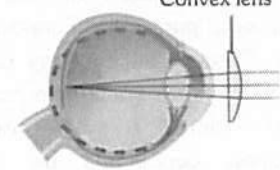
(b) Nearsighted (myopic) eye, uncorrected



(c) Nearsighted (myopic) eye, corrected



(d) Farsighted (hypermetropic) eye, uncorrected



(e) Farsighted (hypermetropic) eye, corrected

Fig : 5.6-28 Diagrammatic representation of eye defects

(2) **Hypermetropia (Long or Far sightedness)**

- (i) Far object is clear, near object is not clear.
 - (ii) Eyeball become short.
 - (iii) Image is formed behind the retina.
 - (iv) Can be removed by convex lens.
- (3) **Astigmatism**
- (i) Curvature of cornea become irregular and image is not clearly form.
 - (ii) Can be removed by cylindrical lens.

(4) **Cataract**

- (i) It is due to defective protein metabolism.
- (ii) During this lens or cornea sometime both become opaque.
- (iii) Operation is needed.

(5) **Glaucoma**

- (i) It is due to increase in intraocular pressure in aqueous chamber.
- (ii) Operation is needed at early stage due to blockage of schlemm's canal.

(6) **Trachoma**

- (i) It is increased in redness of eye and more secretion of watery fluid.
- (ii) It is due to infection of bacteria, chlamydia trachomatis.
- (iii) Due to this follicles may form in conjunctiva.

(7) **Xerophthalmia**

- (i) It is due to deficiency of vitamin A. (A₂)
- (ii) During this conjunctiva or cornea becomes keratinized.
- (iii) It may lead to blindness.

(8) **Strabismus**

- (i) In this type eyeball remain in some what in bended position.
- (ii) It is due to long extra ocular muscles during development of eye.
- (iii) Operation is needed at early stage.
- (iv) Also associated with squint.

(9) **Presbyopia**

- (i) During this power of accommodation of lens decreases due to age factor and defected metabolism.
- (ii) Also known as age sightness.
- (iii) Can be removed by bifocal lens.

(10) **Photophobia** : No clear image in bright light.

(11) **Emmetropia** : Normal vision.

Phonoreceptor and Mechanism of hearing or auditory sensations and equilibrium

Also known as stato-acoustic organ. It is the receptor for balancing and hearing which is sensitive for gravity and sound waves. It is also sensitive in orientation of body. It is also known as mechano receptor because of it change mechanical energy of sound waves into action potential.

Structure of Ear

Ear of mammal is divided into 3 parts –

(1) **External ear** : It is made up of pinna and auditory meatus. Pinna is found in only mammals. Its upper rounded part is

helix and lower is ear lobe. It is made up of adipose connective tissue and elastic cartilage and has ear muscles which are vestigial in case of human beings. Pinna collect the sound waves and drive towards auditory meatus.

Auditory meatus is 25 mm. long canal lined by simple columnar epithelia and made up of fibro elastic cartilage. It possesses ceruminous gland which secrete cerumin (ear wax). Cerumin trap the dust particles and microbes.

Tympanic membrane : It is also called ear drum and present at the junction of auditory meatus and tympanic cavity.

(2) **Middle ear** : The cavity of middle ear is known as tympanic cavity which is enclosed by tympanic bulla bone of skull and filled with air. Middle ear separated from external ear by ear drum and from internal ear by thin bony portion or partition with two openings known as oval and round window.

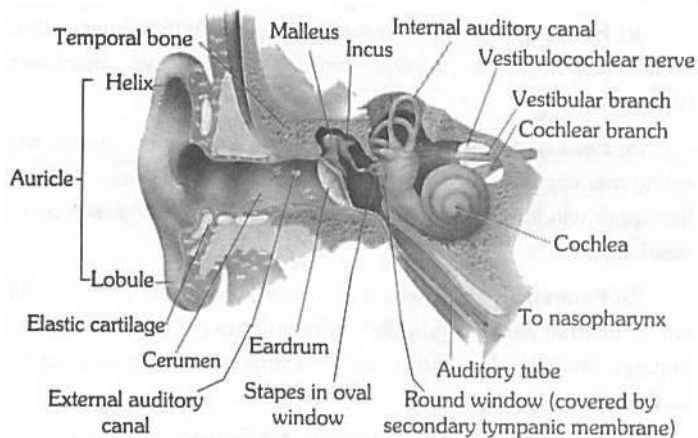


Fig : 5.6-29 Right internal ear

(i) **Ear ossicle** : A chain of three small, movable bones, the auditory or ear ossicles crosses the tympanic cavity. The outer ossicle is attached to the inner surface of the tympanic membrane.

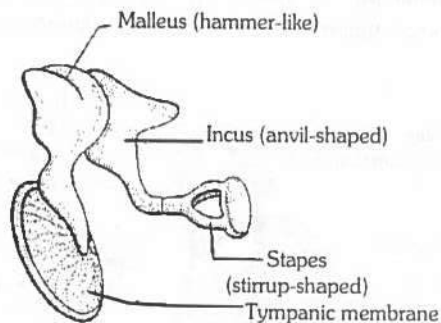


Fig : 5.6-30 Ear ossicles


Table : 5.6-12 Ear ossicles

Ear ossicle	Shape	Modification of
M – Malleus	Hammer shaped	Articular bone of lower jaw.
I – Incus	Anvil shaped	Quadrate bone
S – Stapes	Stirrup shaped	Hyomandibular of columella

In man ear ossicles are known as H.A.S. stapes is the smallest bone of the body. In frog only stapes is present.

(ii) **Joints**

Synovial hinge joint Ball and socket joint



(iii) **Muscles**

Tensor tympani : Limits movements and increases tension on eardrum to prevent damage to inner ear from loud sound.

(iv) **Eustachian tube** : It is made up of elastic cartilage and it connects middle ear to nasopharynx. It maintain equilibrium in and out side of the tympanic membrane. Blocking of eustachian tube impairs hearing due to imperfect vibrations of drum. Eustachian tube is normally closed, it opens during swallowing and yawning.

(v) **Fenestrae** : Between middle ear and internal ear a thin bony membrane is present which possess two apertures (Windows).

(a) **Fenestra ovalis** : It is upper window, connect middle ear to internal ear and guarded by membrane. End of stapes is fit on the upper window. It is towards vestibule so it is also known as *F. vestibuli*.

(b) **Fenestra rotundus** : It is ventral window, connect middle ear to internal ear and guarded by membrane. It is towards scala tympani so it is also known as *F. Tympani* (also known as *F. cochleae*).

(3) **Internal ear (Membranous labyrinth)** : Internal ear is also known as membranous labyrinth and enclosed by bony labyrinth. Bony labyrinth is formed by petriotic bone or petrous. A cavity is present between membranous labyrinth and bony labyrinth known as perilymphatic space. It is filled with perilymph and endolymph is found in membranous labyrinth. The membranous labyrinth consists of 2 parts – Vestibule and Cochlea.

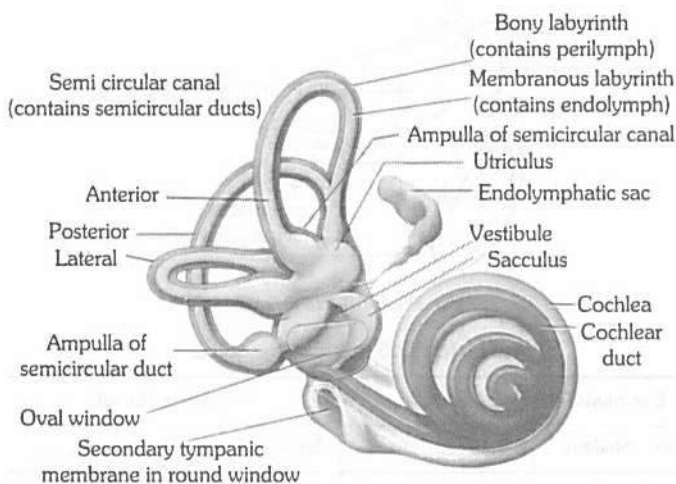


Fig : 5.6-31 Section through the cochlea (Semicircular canals, vestibule and cochlea of the right ear

(i) **Vestibule** : The vestibule is a central sac like part. It further consists of 2 chambers large – Utriculus (Upper) and smaller – sacculus (lower).

(a) **Semicircular canal** : From utriculus 3 semicircular canals arise these are –

- Anterior semicircular canal (Superior)
 - Posterior semicircular canal (Inferior)
 - Horizontal semicircular canal (External)
- They are perpendicular each other.

Crus commune : A common part of anterior and posterior semicircular canal arising from dorsal region of utriculus is known as crus commune.

Ampulla : Terminal part of the each semicircular canal is enlarged to form an ampulla.

Crista : Each ampulla has a sensory spot called crista ampullaris or simply crista, for equilibrium.

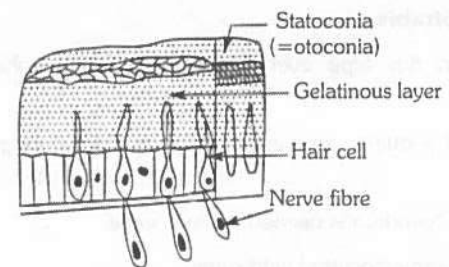
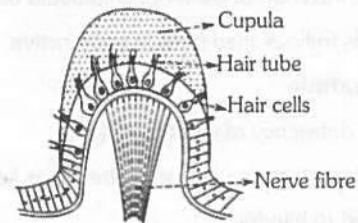


Fig : 5.6-32 Crista and macula of ear

(b) **Sacculus** : It is a lower chamber of vestibule. From the lower part of the sacculus arises a short tube, the ductus reuniens, that joins the cochlear duct.

Ductus endolymphaticus : It is filled with endolymph and arises from the junction of utriculus and sacculus.

Macula : are present in utriculus and sacculus. it is a group of sensory cells. In man (Rabbit) 2 maculas are present. (A crista resembles a macula in structure except that lies on an elevation, the acoustic ridge, its sensory cells have longer "hair", and its gelatinous mass is dome shaped, lacks otoliths and is called cupula.)

Table : 5.6-13 Difference between Crista and Macula

S.No.	Crista	Macula
1.	Found in ampulla of semi-circular canal	Found in vestibule i.e. sacculus and utriculus.
2.	Their total number is 3	Only 2 are present
3.	No otolith	Otolith present
4.	Long auditory hairs	Short auditory hair
5.	Facilitate maintenance of dynamic equilibrium and angular acceleration e.g. rotational movement of head	Help in static equilibrium and linear acceleration e.g. tilting of head or body at rest and rapid forward movement.

Otolith : Also known as otoconia made up of protein and calcium carbonate and present in endolymph.

(ii) **Cochlear duct and Cochlea** : It is a spirally coiled tube (2 – 3 coiling) which is connected to sacculus by a short duct. It is divided into 3 chambers by 2 membranes.

(a) **Scala vestibuli** : Upper chamber filled with – perilymph - connect with middle ear by *F. ovalis*, or oval window.

(b) **Scala media (Real cochlear duct)** : Middle chamber filled with – endolymph.

(c) **Scala tympani** : Lower chamber filled with – perilymph connect with middle ear by *F. Tympani* or round window.

(d) **Reissner's membrane** : Present at the roof of scala media, it separate S.M. to S.V.

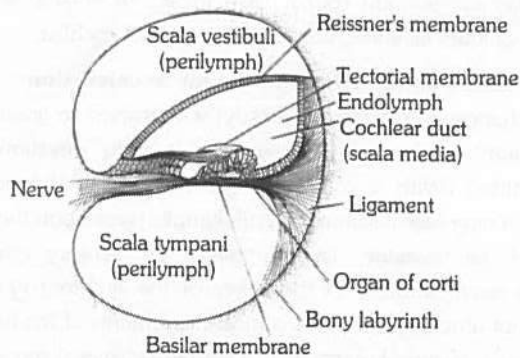


Fig : 5.6-33 Cochlear apparatus in T.S.

(e) **Basilar membrane** : Present at the base of S.M. It is thicker than Reissner's membrane and it separates S.M. to S.T.

(f) **Modiolus** : A bony core around which bony spiral canal of cochlea make $2\frac{3}{4}$ turns or coils in man.

(g) **Helicotrema** : A aperture present in scala media which connect scala vestibuli to scala tympani is known as helicotrema.

(h) **Tectorial membrane** : Tectorial membrane is a leaf like gelatinous structure present at the dorsal side of organ of corti.

(i) **Organ of corti** : Discovered by Italian anatomist Alfonso-Corti. Also known as ridges of corti which are present in basilar membrane. Organ of Corti contains a variety of cells. They receives nutrients from endolymph. The cells of organ of Corti are following types –

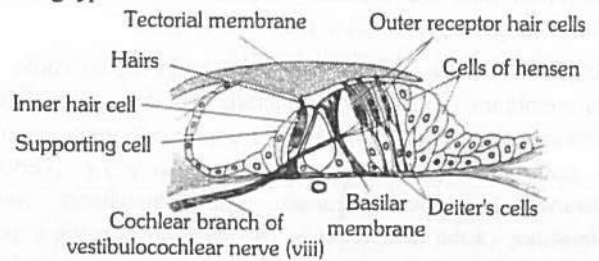



Fig : 5.6-34 Detailed structure of organ of corti (vertical section)

Table : 5.6-14 Characteristics of cells of organs of Corti

Receptor cell (=Hair cells)	Supporting cells	Tectorial membrane	Peripheral membrane
Two type (i)- inner hair cells – in one layer and number 3500, while the (ii) outer hair cells are in 3 – 4 rows (20,000)	Support hair cells, These rest on basilar membrane	Flap of fibrous and gelatinous tissue, the outer right plate is called reticular lamina which is supported by rods or corti anchored to basilar membrane	Has restricted elasticity respond to low to high frequencies within audible region
Hair of outer hair cell extend into scala media and embeded in roof like tectorial membrane.	Provide nutrients and physical support to the hair cells		
Inner hair cells respond to the velocity of movement of the basilar membrane. While the outer hair cells are primarily concerned with the displacement of the basilar membrane by the sound waves.	They are not involved in sound transduction		
Hair cells have a basal body just under the hair. The basal body facilitates transduction of the mechanical signal to a neural signal (electrogenesis)			

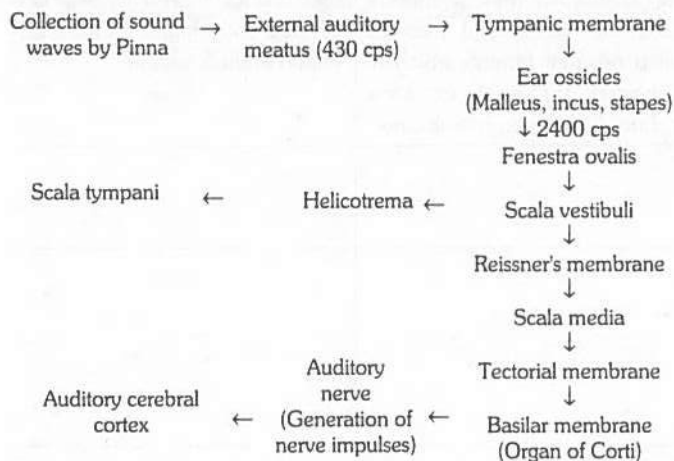
Mechanism of sound perception

Vone Beskey won the Nobel prize for his work on ear. The mechanism found in ear involve two unrelated functions : Hearing and equilibrium.



(1) **Hearing** : The ear not only detects sound but also notes its direction, judges its loudness and determines its pitch (frequency). Sound waves are collected by the pinna and directed inward through the external auditory meatus (frequency 430 cycle per second). Here they strike the tympanic membrane. The latter begins to vibrate at the same frequency as that of the sound waves. From the tympanic membrane, the vibrations are transmitted across the tympanic cavity by the ear ossicles to the membrane of the fenestra ovalis. The force of vibrations is considerably increased in the middle ear by leverage of the ossicles and also by much smaller surface area of the membrane of fenestra ovalis than that of the tympanic membrane. (The frequency is 2400 cycle/sec). Increase in frequency is important because the sound wave are transmitted from air to a fluid medium. The membrane of fenestra ovalis transmits the vibrations to the perilymph of the scala vestibuli and hence via Reissner's membrane to the endolymph in the scala media. From here the vibrations are transferred to the basilar membrane and the perilymph in the scala tympani.

Vibration of the endolymph of the scala media cause the basilar membrane of this chamber vibrate. Vibrations of the basilar membrane make the "sensory hair" of receptor cells in the organ of corti move in the overlying gelatinous membrane (Tectorial membrane) and get distorted. This stimulation causes depolarisation of the receptor cells and initiation of nerve impulse in the fibres of the auditory nerve. The nerve impulse travels via relay centers e.g. spiral ganglion → cochlear nuclei → superior auditory nuclei → inferior colliculi → auditory cortex of cerebrum (The cerebral cortex interprets the impulses as sound). The various steps in the mechanism of hearing



Human ear can hear a frequency of 500 to 5000 hertz (Hz; 1 Hz = 1 cycle/second). However, it can hear the complete range of frequencies from 20 – 20,000 Hz only with intense sound. Sound energy is measured in terms of units called decibels (dB). Sounds in our city homes average 40 – 50 dB, but street noise averages 70 – 80 dB. Sounds upto 80 dB are considered bearable by man, but higher sound intensity are hazardous, causing nervous stress, irritability, increased blood pressure etc. Non stop noise of 90 or more dB produces temporary deafness. 160 dB sound can cause total deafness by rupturing our ear drum. Sound becomes uncomfortable to normal ear at about 120 dB.

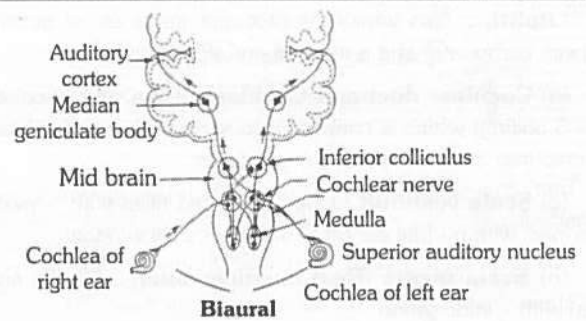


Fig : 5.6-35 Pathway of sound perception from organ of corti in cochlea to auditory cortex of cerebrum

(2) **Equilibrium** : Sound become painful above 140 dB. Exposure to certain antibiotics, such as gentamycin some anticancer drugs, loud sound, loud music, or engine rear of jet planes, vacuum cleaners, damages hair cells of cochlea.

(i) **Static equilibrium and linear acceleration** : Maculae detect changes in the head (or body) with respect to gravity (static equilibrium) and in the movement in one direction (linear acceleration). With a change in the position of the body, the otoliths, being heavier than the endolymph, press upon the sensory hairs of the maculae. This stimulates the sensory cells which initiates nerve impulse in the fibres of the auditory nerve. The macula of utricle responds to vertical movements of the head, and the macula of saccule responds to lateral (sideways) movement of the head.

On rapid forward movement, the otoliths, because of having greater inertia than the surrounding endolymph, lag behind and press back the sensory hair, stimulating the sensory cells to generate nerve impulses.

(ii) **Dynamic equilibrium** : Cristae detect turning or rotational movements of the head (angular acceleration). When the head is turned, the endolymph in the semicircular ducts, due to its inertia, does not move as fast as the head and the sensory cells of the crista, but continues to move after the head stops moving. Because of this difference in the rate of movement, the sensory hair of the cristae are swept through the endolymph and become bent over. This disturbance stimulates the sensory cells and sets up action potential in the fibres of the auditory nerve, which transmits it to the brain. Since the three semicircular ducts are arranged in three different planes, a movement of the head in any direction will stimulate the sensory cells of at least one crista.

Defects of ear

- (1) **Labyrinthine disease** : Malfunction of inner ear.
- (2) **Meniere's disease** : Loss of hearing due to defect in cochlea.
- (3) **Otitis media** : Acute infection of middle ear.
- (4) **Eustachitis** : Inflammation of eustachian tube.
- (5) **Myringitis (Tympanitis)** : Inflammation of eardrum.
- (6) **Otalgia** : Earache (pain in ear)

T Tips & Tricks

- ✍ Tela choroidea is the term used for epithalamus and pia mater fused.
- ✍ Tela choroidea is made up of epithelium and blood vessels.
- ✍ Ataxia means lacks of muscle coordination. Damage to cerebellum is characterized by ataxia.
- ✍ Dyslexia involves an inability of an individual to comprehend written language.
- ✍ Multiple sclerosis is the destruction of myelin sheath of neurons of CNS.
- ✍ An American scientist Roger Sperry got Nobel Prize in 1981 for his outstanding work on split brain theory.
- ✍ Parkinson's disease or Paralysis agitans is a defect of brain.
- ✍ Parkinsonism is characterised by tremors and progressive rigidity of limbs caused by a degeneration of brain neurons and a neurotransmitter called dopamine.
- ✍ Avian brain has large sized optic lobes to see the objects on the earth while flying so is called eye brain, while fish brain has large sized olfactory lobes to smell the prey from a distance so is called nose brain.
- ✍ In fishes : Cerebrum is not differentiated in two cerebral hemispheres.
- ✍ Hypothalamus has additional lobes to note pressure changes.
- ✍ In reptilian brain, pineal eye (parietal body) present in front of pineal body.
- ✍ Grey matter of spinal cord of frog is rectangular while it is butterfly-shaped in mammals.
- ✍ Central canal : Cavity of spinal cord.
- ✍ Optic bigemina : Two optic lobes in brain and are found from fishes to birds.
- ✍ Optic lobes of man are solid and have no optocoel but those of frog have optocoel.
- ✍ Optic tectum : Dorsal thick wall of optic lobe.
- ✍ Cerebellum is also called little brain.
- ✍ Thalami of diencephalon act as relay centres as well as gate keepers of brain.
- ✍ Optic chiasma is meant for binocular vision.
- ✍ Olfactory lobes of human brain have no rhinocoel while those of frog have rhinocoel.
- ✍ Man and birds are less dependent upon smell so olfactory lobes are small sized but are large sized in cartilage fishes (dog fish), dogs and reptiles are more dependent upon smell.
- ✍ Cerebellum is large sized in fishes, birds and rabbit due to their multidirectional movements and increased dependency on balance.

- ✍ Stimulus for hunger : In February 1998, an American scientist Dr. Masashi Yanagisawa reported that a drop of sugar level in blood stimulates the appetite centres of lateral hypothalamus to release oraxin hormone (Gr. Oraxis = hunger) which stimulates hunger.
- ✍ Nervous disorders
 - Agnosia : Failure to recognize;
 - Alexia : Failure to read;
 - Agraphia : Failure to write;
 - Aphasia : Failure to speak (due to injury to Broca's area)
 - Analgesia : Loss of sensation of pain;
 - Anesthesia : Loss of feeling;
 - Insomnia : Inability to sleep;
 - Amnesia : Partial or complete loss of memory;
 - Coma : Complete loss of consciousness.
 - Aproxia : Inability to carry out purposeful movements.
- ✍ Multiple sclerosis : Progressive degenerative disease of CNS and is characterized by many hard scar tissues.
- ✍ Brain stem : Diencephalon + mid brain + pons + medulla oblongata.
- ✍ Cerebro vascular accident (C.V.A) or stroke : Blocking of blood supply of a part of brain.
- ✍ Alzheimer : It is the disease appearing usually after 65 year. It is characterized by dementia usually. Usually in this disease ACh producing neurons of cerebral cortex and hippocampal lobe are degenerated. It is also seen that a amyloid protein is accumulated in the brain. It is the matter of research.
- ✍ Commissure : The band of nerve fibres between two similar ganglia.
- ✍ Associate fibres : If joining fibre are joining two similar structure in same halves then, they are called associate fibre.
- ✍ The rate of conduction in myelinated fibre of a mammal is very high because action potential jumps from node to node.
- ✍ The jumping of action potential from node to node (of Ranvier) in a fibre is called saltatory conduction.
- ✍ Nissl's or trigoid granules are present in the neuron and are made up of RNA, ribosome and RER. These granules help in excretion and nutrition.
- ✍ Intelligence quotient (I.Q.) is the ratio of mental age to chronological age multiplied by 100.
- ✍ Corpora striata, genu and splenium is found in cerebrum.
- ✍ Neurons stops dividing after birth.
- ✍ Optocoel is not found in mammalian brain.
- ✍ The pneumotoxic centre is found in pons.
- ✍ Transmission of nerve impulse can be recorded with the help of oscilloscope.
- ✍ The ramus communicans of the spinal nerve joins the sympathetic chain.
- ✍ Autonomous nervous system has paired chain ganglia.
- ✍ Paralysis of jaw muscles is due to loss of function of Vth cranial nerve.
- ✍ Bipolar nerve cell and ganglia cell are found in the retina.
- ✍ Arbor vitae are composed of white matter.

972 Neural Control and Coordination

- ✍ IIIrd, IVth and Vth cranial nerves control eye-ball movement.
- ✍ A cavity in the ventricle of a brain is known as cerebral aqua.
- ✍ VII, IX, X, XI and XIIth cranial nerve originates from medulla oblongata.
- ✍ Cycling is an example of conditioned reflex.
- ✍ The ganglia of sympathetic and central nervous system in frog develops from the neural crest cells.
- ✍ Cerebellum of post brain involved in loss of control when a person drinks alcohol.
- ✍ The maximum current required to stimulate a nerve is called rheobase or threshold current or firing level of impulse. It is about 15 mv.
- ✍ Earthworm has both sensory and motor neurons.
- ✍ The glial cells that form the blood brain barrier by lining brain capillaries are the astrocytes.
- ✍ Axo-axentic is the condition when direction of nerve impulse is reversed.
- ✍ Unipolar nerve cells are found in vertebrates embryo.
- ✍ Saltatory conduction is found in all vertebrates.
- ✍ Corpus callosum is absent in the brain of prototherians and metatherians both.
- ✍ Degeneration or imperfect development of corpus callosum in human brain results in a neurological disorder called schizophrenia.
- ✍ γ -amino butyric acid is a neurotransmitter.
- ✍ Acetylcholine is the cardiac inhibitor.
- ✍ 5-Hydroxy tryptamine is a chemical transmitter.
- ✍ Spike phase of action potential is 2 m. sec.
- ✍ Sylvian fissure divides the brain of rabbit into frontal lobe and temporal lobe.
- ✍ Dorsal root has the ganglion made of pseudounipolar neurons.
- ✍ All cell bodies of afferent fibres lie in the dorsal root ganglion.
- ✍ EEG - Electro-Encephalogram : Electrical tracing of the cerebral cortex is call EEG Berger in 1929 was first to record EEG. Instrument for the recording is Electroencephalograph or cathode ray oscilloscope.
- ✍ It is record of brain wave. Brain waves are of following type
 - (i) α -wave : These are rhythmic waves (8-13 cycles per second. These are produced in normal awaking condition. These disappear in sleep.
 - (ii) β -wave ; 14-30 cycle per second. These are produced when nervous system is active e.g. Mental work.
 - (iii) θ -wave : 5-8 cycle per second. Produced in children.
 - (iv) δ -wave : 1-5 cycle per second. In normal condition these are produced in awake infants. These are produced in deep sleep. In damage condition of the brain waves may produce in awaking condition in adults.
- ✍ Fundamental character of chordates is the presence of dorsal hollow nerve chord.
- ✍ Somesthetic & taste area present in parietal lobe of cerebrum.
- ✍ Epilepsy : Is second common neurological disorder is characterized by short, recurrent, periodic attacks of motor, sensory, or psychological mal function. The attacks called epileptic seizures are initiated by abnormal, synchronus electrical discharge from millions of Neurons in brain. Due to this, a person undergoing an attack may contract skeletal muscles involuntarily, light, noise, smells may be sensed when eyes, ears, nose have not been stimulated. Epilepsy has causes, including brain damage at birth (Most common cause), hypoglycemia, hypocalcaemia, hypoxia, uremia, encephalitis, meningitis, and tumors.
- ✍ Nystagmus – An uncontrolled oscillation of the eyes, is one of the symptoms of an inner-ear disease called Meniere's disease (from Prosper Meniere, French physician, 1799-1862).
- ✍ Cones are absent in nocturnal animals like shrews, hedge hogs, rodents and bats.
- ✍ During night the eyes of carnivores like cat, dog, lion, seal glow. It is due to tapetum lucidum a reflecting layer next to retina, which is made of crystalline layer with zinc, cysteine and guanine.
- ✍ Bees can see ultraviolet light.
- ✍ The normal eye is known as emmetropic.
- ✍ Deer has biggest eyes in proportion to body size.
- ✍ Except rabbit and man, harderian glands are found in whale, mice, shrews and in reptiles.
- ✍ Nocturnal animals have more rods than cones in their eye. The image formed has no colour but is black or grey, the edges are not sharp.
- ✍ Colour blindness – It is known as daltonism. It is in between red and green colour. It is genetic defect.
- ✍ Colour vision is due to presence of specialise cone cell in Retina which value the sensitivity for different colours.
- ✍ Night blindness – During this rhodopsin is not resynthesized or regenerate in dim light.
- ✍ Monocular vision found in frog, rabbit and horse.
- ✍ Binocular vision found in primates, ape, monkey.
- ✍ Colour vision found in fishes, reptiles, amphibia.
- ✍ Sty – Sebaceous gland infection leading to its inflammation.
- ✍ There are only four basic modalities of taste, which are sensed most acutely in particular regions of the tongue. These are sweet (tip of the tongue), sour (sides of the tongue), bitter (back of the tongue) and salty (over most of the tongue.)
- ✍ Iris is the third portion of the vascular tunic.
- ✍ Atropine is a chemical used by doctors to dilate the pupil before testing.
- ✍ Photopic vision is associated with cones.
- ✍ Cornea grafting : Cornea can be removed from a dead man's eyes, stored and grafted on another person's eye to restore vision, cornea transplantation is successful because it lacks blood vessels. Eye donation is a noble act.

Ordinary Thinking

Objective Questions

Development of central nervous system in human

- Which one of the following is essential for the formation of myelin sheath [CBSE PMT 1990]
 - Zinc
 - Sodium
 - Iron
 - Phosphorus
- Mammalian brain differs from an amphibian brain in possessing [CPMT 1993; AFMC 1999; BHU 2008]
 - Olfactory lobe
 - Hypothalamus
 - Corpus callosum
 - Cerebellum
- Brain is [MP PMT 1994, 97, 2006; CPMT 1995, 98; RPMT 1995, 99, 2000, 06; Odisha JEE 2010]
 - Ectodermal
 - Mesodermal
 - Endodermal
 - Mesendodermal
- Which cell stops dividing after birth [MP PMT 1997]

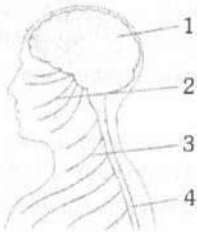
Or

Largest cell in body is [CPMT 1992, 93]

 - Neuron
 - Glial
 - Epithelium
 - Liver
- The second cranial nerve in human originates from

Or

The second cranial nerve of frog is distributed in

 - Ciliary muscles of eye
 - Retina only
 - Retina and lens
 - Ocular muscles of eye
- The ganglia of sympathetic and the central nervous system in frog develops from the [AIIMS 2002]
 - Neural cell
 - Notochordal cells
 - Neural plate cells
 - Neural crest cells
- Which is activated in stress condition [DPMT 2003]
 - Sympathetic
 - Parasympathetic
 - Somatic
 - Whole ANS
- The autonomic nervous system has control over [Kerala CET 2003; MP PMT 2007]
 - Reflex action
 - Skeletal muscles
 - Sense organs
 - Internal organs
- The given diagram indicates part of the human body, the structures belonging to the central nervous system are numbered [NCERT]
 

- 3 and 4
- 1 and 4
- 2 and 3
- 1 and 3

Parts of nervous system

- In man which one of the following cranial nerve is associated with the sense of body balance [MP PMT 1992]
 - VI
 - VII
 - VIII
 - IX
- How many pairs of sympathetic ganglia are present in ANS [MHCET 2015]
 - 10
 - 12
 - 22
 - 31
- If a person has lost his memory in an accident, the following part of the brain have got injured [NCERT; CBSE PMT 1992; MP PMT 1994]
 - Diencephalon
 - Medulla oblongata
 - Cerebellum
 - Cerebrum
- The hind brain consists of [CBSE PMT 1992; Kerala PMT 2009; CBSE PMT (Pre.) 2012]
 - Pons + cerebellum
 - Hypothalamus + cerebellum
 - Medulla oblongata + cerebellum
 - Medulla oblongata + cerebellum + pons
- Which of the following regions of the brain is incorrectly paired with its function [AIPMT (Cancelled) 2015]
 - Cerebellum – Language comprehension
 - Corpus callosum – communication between the left and right cerebral cortices
 - Cerebrum – calculation and contemplation
 - Medulla oblongata – homeostatic control
- Which one of the following is responsible for the control of reflex action [AFMC 1999]
 - Sensory nerves
 - Motor nerves
 - Sympathetic nervous system
 - Central nervous system
- The number of spinal nerves in man is [KCET 1999; WB JEE 2012]
 - 27 pairs
 - 31 pairs
 - 37 pairs
 - 47 pairs
- Which of the following cranial nerves are involved in the movement of eye [MH CET 2015]
 - Optic, oculomotor, abducens
 - Oculomotor, abducens, trochlear
 - Trochlear, abducens and optic
 - Abducens, optic, trochlear, oculomotor
- The smallest cranial nerve in human being is
 - Trochlear
 - Ophthalmic
 - Abducens
 - Vagus
- Post-ganglionic nerve fibres of sympathetic system are [DPMT 2006]
 - Adrenergic
 - Cholinergic
 - Both (a) and (b)
 - None of these
- The supporting and nutritive cells found in the brain are [DPMT 2006]

Or

Ventricles of brain are lined by the cells called [MP PMT 1997]

 - Ependymal cells
 - Microglia
 - Astrocytes
 - Oligodendrocytes

12. Identify the origin of sympathetic nerve fibres and the location of their ganglia [CBSE PMT 1995; AIIMS 1998; BVP 2000; CPMT 2010; WB JEE 2012]
- They arise from thoraco-lumber region of spinal cord and form ganglia just beside the vertebral column
 - They arise from thoraco-cervical region of spinal cord and form ganglia just beside the vertebral column
 - They arise from cranio-sacral region of spinal cord and form ganglia very close to effector organ.
 - They arise from thoraco-lumber region of spinal cord and form ganglia very close to effector organ

13. Neural stimulation in visceral organ in human being is done by [CBSE PMT 1996]
- Sympathetic and parasympathetic nerves and is under involuntary action
 - Sympathetic nerves and is under voluntary action
 - Sympathetic and parasympathetic nerves and is under voluntary action
 - Parasympathetic nerves and is under voluntary action

14. The third ventricle of the brain is situated in the [AMU (Med.) 2010]
- Base of telencephalon
 - Roof of metencephalon
 - Roof of diencephalon
 - Base of myelencephalon

15. The purely motor cranial nerve is [Pb. PMT 2005]
- Facial
 - Vagus
 - Trigeminal
 - Spinal accessory

16. Foramen of Monro is an aperture between [CBSE PMT 1992]
- 2nd and 3rd ventricle
 - Diocoel and metacoel
 - Rhinocoel and diocoel
 - 3rd and 4th ventricle

17. Hypothalamus of the brain is not involved in this function [KCET 2012]
- Sleep-wake cycle
 - Osmoregulation and thirst
 - Temperature control
 - Accuracy of muscular movement

18. Match List I with List II and select the correct option

List I		List II	
A.	Sacral nerves	1.	1 pair
B.	Thoracic nerves	2.	8 pairs
C.	Coccygeal nerves	3.	7 pairs
D.	Cervical nerves	4.	12 pairs
E.	Lumbar nerves	5.	5 pairs

[Kerala PMT 2005, 08]

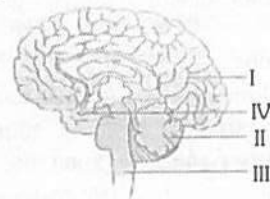
- A - 4, B - 1, C - 3, D - 2, E - 5
- A - 5, B - 3, C - 1, D - 4, E - 2
- A - 3, B - 4, C - 2, D - 5, E - 1
- A - 2, B - 5, C - 3, D - 1, E - 4
- A - 5, B - 4, C - 1, D - 2, E - 5

19. In a myelinated neuron, two adjacent myelin sheaths are separated by gaps called [Kerala PMT 2008]
- Nodes of Ranvier
 - Synaptic cleft
 - Schwann cells
 - Synaptic knob
 - Neural plate

20. The branched tree like structure present in cerebellum is Or
The tree of life is [DPMT 1993; Manipal 2005; BHU 2005]

- Arbor vitae
- Arboreal
- Archenteron
- Areole

21. The given figure is that of the human brain



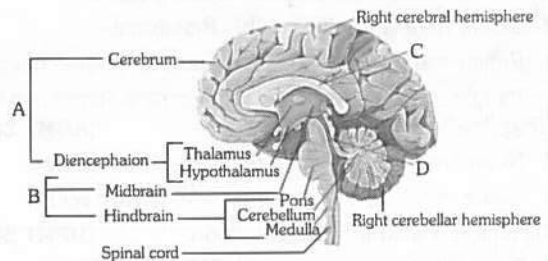
Identify the part that controls intelligence and memory is labelled [NCERT]

- IV
- III
- II
- I

22. Purely motor nerve is [BHU 1999, 2004; CPMT 2001, 02; MP PMT 2002, 06; MH CET 2003]

- Optic
- Abducens
- Ophthalmic
- Palatinus

23. See the following diagram and identify A, B, C and D [NCERT]



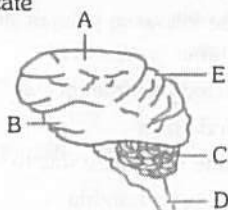
- A - Brainstem, B - Forebrain, C - Cerebral aqueduct, D - Corpus callosum
- A - Brainstem, B - Forebrain, C - Corpus callosum, D - Cerebral aqueduct
- A - Forebrain, B - Brainstem, C - Cerebral aqueduct, D - Corpus callosum
- A - Forebrain, B - Brainstem, C - Corpus callosum, D - Cerebral aqueduct

24. Pituicytes are under the control of [Odisha JEE 2012]
- Adenohypophysis
 - Hypothalamus
 - Neurohypophysis
 - Both (a) and (c)

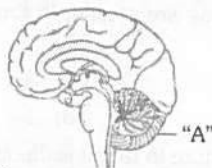
25. Which one of the following statement is correct [CBSE PMT 2006]

- Neither hormones control neural activity nor the neurons control endocrine activity
- Endocrine glands regulate neural activity, but not vice versa
- Neurons regulate endocrine activity, but not vice versa
- Endocrine glands regulate neural activity, and nervous system regulates endocrine glands

26. The given diagram is the lateral view of the human brain, parts are indicated by alphabets. Select the answer in which these alphabets have been correctly paired with the parts which they indicate [NCERT]



- (a) A – Frontal lobe, B – Temporal lobe, C – Cerebellum, D – Medulla oblongata, E – Parietal lobe
 (b) A – Temporal lobe, B – Parietal lobe, C – Cerebrum, D – Medulla oblongata, E – Frontal lobe
 (c) A – Frontal lobe, B – Temporal lobe, C – Cerebrum, D – Medulla oblongata, E – Occipital lobe
 (d) A – Temporal lobe, B – Parietal lobe, C – Cerebellum, D – Medulla oblongata, E – Frontal lobe
27. Parasympathetic ganglia are present in [AFMC 2012]
 (a) Head and neck
 (b) Chains of lateral ganglia
 (c) Grey matter of thoracic and lumbar region of spinal cord
 (d) All of these
28. Consider the given diagram and identify "A" [NCERT]



- (a) Medulla oblongata (b) Cerebellum
 (c) Midbrain (d) Pons
29. Blood-brain barrier is formed by [BHU 2012]
 (a) Microglial cells (b) Astrocytes
 (c) Oligodendrocytes (d) Ependymal cells
30. Which of the following cranial nerves innervates heart, stomach and lungs [CBSE PMT 1990; MP PMT 1996; Odisha JEE 2009]
Or
 Which of the cranial nerve is mixed [WB JEE 2012]
 (a) Vagus (b) Accessory
 (c) Trigeminal (d) Trochlear
31. Parasympathetic nervous system increases the activity of [DPMT 1992]
 (a) Gut, iris and urinary bladder
 (b) Heart, adrenal and sweat gland
 (c) Heart, pancreas and lacrimal gland
 (d) Lacrimal gland and sweat gland
32. The nervous strip connecting both the cerebral hemispheres in the rabbit is [NCERT; MP PMT 1994, 95; RPMT 1995; CPMT 1995; MH CET 2004, 06; WB JEE 2008; Kerala PMT 2011]
 (a) Corpus callosum (b) Corpus albicans
 (c) Corpus stratum (d) Corpus spongiosum

33. The thermoregulatory centre is situated in [AIIMS 1993, 2000; KCET 2000; CPMT 2001, 09; AFMC 2003]

Or

The control of blood sugar level, osmoregulation and thermoregulation are the function of [CBSE PMT 1993]

Or

The appetite and satiety centres in the brain of man are located in the region of the [CPMT 2009]

- (a) Spinal cord (b) Pituitary body
 (c) Cerebellum (d) Hypothalamus
34. Nissl's granules are present in the and are made up of respectively [CBSE PMT 1997; BVP 2001; RPMT 2006]
 (a) Muscle cells and deoxyribo nucleic acid
 (b) Mast cells and RNA
 (c) Osteocytes and DNA
 (d) Neuron and RNA
35. During the course of evolution which part of the brain has shown maximum increase in size [Odisha JEE 2009]
 (a) Mid brain (b) Fore brain
 (c) Hind brain (d) All of the above
36. Skeletal muscles are controlled by [DUMET 2009]
 (a) Sympathetic nerves (b) Parasympathetic nerves
 (c) Somatic nerves (d) Autonomic nerves
37. Select the answer with correct matching of the structure, its location and function [CBSE PMT (Mains) 2010; WB JEE 2016]

	Structure	Location	Function
(a)	Eustachian tube	Anterior part of internal ear	Equalizes air pressure on either sides of tympanic membrane
(b)	Cerebellum	Mid brain	Controls respiration and gastric secretions
(c)	Hypothalamus	Fore brain	Controls body temperature, urge for eating and drinking
(d)	Blind spot	Near the place where optic nerve leaves the eye	Rods and cones are present but inactive here

38. Integration of the visual, tactile and auditory inputs occurs in the [Kerala PMT 2012]

Or

Crura cerebrae is found in [DPMT 1993]

- (a) Peripheral nervous system
 (b) Corpus callosum
 (c) Limbic system
 (d) Medulla oblongata
 (e) Midbrain
39. Reflex action immediately involves [NCERT; BHU 2003; Kerala CET 2005]
 (a) Spinal cord (b) Cerebellum
 (c) Medulla oblongata (d) Optical lobe
40. Parkinsonism is related with [CBSE PMT 2001]
 (a) Brain (b) Spinal cord
 (c) Cranial nerves (d) Spinal nerves

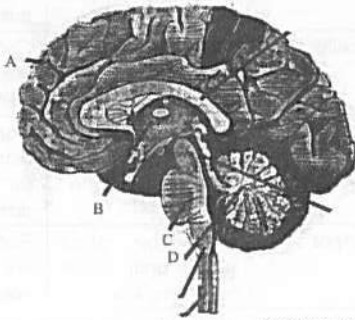
976 Neural Control and Coordination

41. Hearing is controlled by [MH CET 2005]
 (a) Cerebral lobes (b) Hypothalamus
 (c) Temporal lobe (d) Cerebellum
42. In rabbit, optic lobes are small because the eye sight is controlled by [RPMT 2001]
 (a) Temporal lobe (b) Occipital lobe
 (c) Frontal lobe (d) Parietal lobe
43. All spinal nerves are [RPMT 1999]
 (a) Motor (b) Sensory
 (c) Mixed (d) None of the above
44. The correct sequence of meninges from outer to the inner side is [DPMT 2007]
 (a) Arachnoid – piamater – duramater
 (b) Arachnoid – duramater – piamater
 (c) Piamater – arachnoid – duramater
 (d) Duramater – arachnoid – piamater
45. Body posture, equilibrium and rapid muscular activities are controlled by [AIIMS 1993; MP PMT 1995; MH CET 2006; WB JEE 2008; Odisha JEE 2012]

Or

The part of human hind brain that is responsible for hand eye coordination is [Odisha JEE 2009]

- (a) Cerebellum
 (b) Thalamus
 (c) Hippocampus
 (d) Temporal lobe of cerebrum
46. A sagittal section of human brain is shown here. Identify at least two labels from A-D



[NEET (Karnataka) 2013]

- (a) C-Mid brain, D-Cerebellum
 (b) A-Cerebrum, C-Pons
 (c) B-Corpus callosum, D-Medulla
 (d) A-Cerebral hemispheres, B-Cerebellum
47. How many cranial nerves found in the amniota [RPMT 2001]
 (a) 6 pairs (b) 8 pairs
 (c) 12 pairs (d) 10 pairs
48. Which of the following cranial nerves is not a motor nerve [MP PMT 2004]
 (a) II (b) III
 (c) IV (d) XII
49. What is found in the periphery of spinal cord [MP PMT 1996]
 (a) Grey matter (b) Myelinated nerve
 (c) White matter (d) Notochord

50. Which foramen is paired in mammalian brain [MP PMT 2009]
 (a) Foramen of Luschka (b) Foramen of Magendie
 (c) Foramen of Monro (d) Inter-ventricular foramen
51. Which one of the following pairs of structures distinguishes a nerve cell from other types of cell [CBSE PMT 2007]
 (a) Perikaryon and dendrites
 (b) Vacuoles and fibres
 (c) Flagellum and medullary sheath
 (d) Nucleus and mitochondria
52. Which one of the following cranial nerves is carrying the nerve fibres originating from the Edinger-Westphal nucleus [WB JEE 2010]
 (a) Oculomotor (b) Trochlear
 (c) Abducens (d) Vagus
53. Among the following characteristics, indicate the correct combinations applicable to conditional reflex
 P. Acquired by practice or learning
 Q. Not acquired by birth
 R. Does not abolish by lack of practice
 S. Participation of cerebral cortex
 T. Originates spontaneously [WB JEE 2012]
 (a) P, Q, R (b) P, Q, S
 (c) P, R, T (d) Q, R, T
54. How many laminae are present in the grey matter of spinal cord [WB JEE 2010]
 (a) Four (b) Six
 (c) Eight (d) Ten
55. Which brain structure in rabbit is directly vision related [BHU 2003]
 (a) Corpus albicans (b) Hippocampal lobe
 (c) Corpus callosum (d) Corpora quadrigemina
56. A boy learns typewriting and harmonium at the same time. He finds harmonium more easy to learn. This is
 (a) Conditioned reflex (b) Short term homeostasis
 (c) Long term homeostasis (d) Residual learning
57. Which of the following is not related to the autonomic nervous system [WB JEE 2010]
 (a) Peristalsis (b) Digestion
 (c) Excretion (d) Memory and learning
58. Which is thickened to form organ of Corti [MP PMT 2009]
 (a) Reissner's membrane (b) Basilar membrane
 (c) Tectorial membrane (d) All of the above
59. Which is a wrong relation
 (a) Conditioned reflex – Hodgkins
 (b) Blood circulation – W. Harvey
 (c) DNA double helix model – Watson and Crick
 (d) None
60. Which of the following is the immediate covering of a nerve fibre [MP PMT 1992]
 (a) Sarcoplasm (b) Perineurium
 (c) Epineurium (d) Endoneurium

61. The nerves leading to the central nervous system are called [AIIMS 1993]
 (a) Efferent (b) Afferent
 (c) Motor (d) None
62. If frog's brain is crushed, even then its leg moves on pinpointing. It is called [AIIMS 2001]
 (a) Simple reflex
 (b) Conditional reflex
 (c) Neurotransmitter function
 (d) Autonomic nerve condition
63. Metacoel is the cavity in the [CBSE PMT 1993; DPMT 1993]
 (a) Cerebral hemispheres (b) Diencephalon
 (c) Cerebellum (d) Medulla oblongata
64. The innermost meninx surrounding the central nervous system in frog and man respectively are [JIPMER 1993]
 (a) Pia mater and pia mater
 (b) Arachnoid and pia mater
 (c) Pia mater and duramater
 (d) Arachnoid and duramater
65. Which cranial nerve has the highest number of branches [CBSE PMT 1999, 2000; CPMT 2000; AFMC 2003]
 (a) Trigeminal (b) Facial nerve
 (c) Vagus nerve (d) None of these
66. Broca's area in human brain controls [BHU 2000]
 (a) Movement of tongue (b) Breathing and hiccup
 (c) Movement of vocal cords (d) Both (a) and (c)
67. The membranes enclosing the brain and spinal cord are known as [DPMT 1993]
 (a) Meninges (b) Meningitis
 (c) Nephron (d) Axon
68. The anterior choroid plexus in the brain of man covers [AIIMS 1993]
 (a) Corpora bigemina (b) Medulla oblongata
 (c) Diencephalon (d) Mesencephalon
69. Nerve cells do not divide because they do not have [BHU 2005]
 (a) Nucleus (b) Centrosome
 (c) Golgi body (d) Mitochondria
70. Which of the following nerve innervates upper jaw of frog [RPMT 2000]
 (a) Maxillary (b) Pathetic
 (c) Palatine (d) Oculomotor
71. Which part of the human brain is largest [WB JEE 2009]
 (a) Cerebellum (b) Thalamus
 (c) Cerebrum (d) Medulla
72. The spinal cord extends from the brain through [DPMT 1993]
 Or
 The medulla oblongata of the brain passes out through [NCERT]
 (a) Foramen Magnum (b) Ister
 (c) Anterior commissure (d) Foramen of Monro
73. The nerve related with diaphragm is [MP PMT 1999]
 (a) Vagus (b) Phrenic
 (c) Trigeminal (d) Glossopharyngeal
74. Ister or cerebral aqueduct or aqueduct of Sylvius [DPMT 2004; WB JEE 2012]
 (a) In the third ventricle
 (b) In the second ventricle
 (c) Between the third and the fourth ventricles
 (d) In the lateral ventricles
75. The medulla oblongata encloses the [DPMT 1993]
 (a) Fourth ventricle (b) Second ventricle
 (c) Optic lobe (d) Otic capsule
76. Main function of cerebellum is [MP PMT 1999]
 (a) Balancing (b) To see
 (c) To hear (d) Remembering
77. Foramen of Monro is [CMC Vellore 1993; CPMT 1994]
 (a) Gap in pelvic girdle of rabbit
 (b) Foramen in the skull of frog
 (c) Space in brain of frog and rabbit
 (d) Pore in the inter-auricular septum in a mammalian heart
78. Comprehension of spoken and written words take place in the region of [WB JEE 2010]
 (a) Association area (b) Motor area
 (c) Wernicke's area (d) Broca's area
79. Four healthy people in their twenties got involved in injuries resulting in damage and death of few cells of the following. Which of the cells are least likely to be replaced by new cells [CBSE PMT 2005; RPMT 2006]
 (a) Osteocytes (b) Malpighian layer of the skin
 (c) Liver cells (d) Neurons
80. Simple two neuron reflex arc involves [MP PMT 1998]
 (a) Sensory neuron (b) Spinal cord
 (c) Effector neuron (d) All the above
81. The number of spinal nerves in rabbit is [RPMT 2000]
 (a) 27 pairs (b) 31 pairs
 (c) 37 pairs (d) 47 pairs
82. Fifth cranial nerve of frog is called [CPMT 2000; BVP 2001; BHU 2006; AFMC 2010]
 (a) Optic nerve (b) Vagus nerve
 (c) Trigeminal nerve (d) Ophthalmic nerve
83. Corpus callosum is found in the brain of [MP PMT 2000; KCET 2001]
 (a) Elephant (b) Pigeon
 (c) Crocodile (d) Frog
84. Reflex action is [CPMT 2010]
 (a) Stimulus → sensory → motor → response
 (b) Stimulus → motor → sensory → response
 (c) Reception → motor → sensory → response
 (d) Sensory → stimulus → motor → response
85. Autonomic nervous system is
 (a) Paired chain ganglia (b) Brain and spinal cord
 (c) Sense organs (d) Cerebral hemispheres
86. Cerebrospinal fluid is produced by [MP PMT 1997; Odisha JEE 2005]
 (a) Ependymal cells (b) Choroid plexus
 (c) Neuroglial cells (d) Neurons

978 Neural Control and Coordination

87. Parasympathetic nerves arise from which region of the nervous system [CPMT 2010]
 (a) Thoracolumbar (b) Cervical
 (c) Craniosacral (d) Lumbar
88. In a man, abducens nerve is injured. Which one of the following functions will be affected [CBSE PMT 2005]
 (a) Movement of eye ball (b) Swallowing
 (c) Movement of the tongue (d) Movement of the neck
89. Twelve pairs of ribs and twelve pairs of cranial nerves are found in [BVP 2002; HP PMT 2005]
 (a) Fish (b) Frog
 (c) Lizard (d) Man
90. Pneumotaxic centre which can moderate the functions of the respiratory rhythm centre is present at [NCERT; Kerala PMT 2011]
 (a) Pons region of brain
 (b) Thalamus
 (c) Spinal cord
 (d) Right cerebral hemisphere
 (e) Left cerebral hemisphere
91. Secretion of which of the following is under neurosecretory nerve axons [AIIMS 1998]
 (a) Pineal (b) Adrenal cortex
 (c) Anterior pituitary (d) Posterior pituitary
92. Identify the wrong statement about frog [Kerala PMT 2012]
 (a) Parathyroid and pineal body are present
 (b) There are ten cranial nerves only
 (c) Optic lobes are situated in the mid brain
 (d) The ventricle opens into the conus arteriosus
 (e) Its an ureotelic organism
93. Which of the following has non-myelinated nerve fibres [BHU 2000]
 (a) Optic nerves (b) Cranial nerves
 (c) Spinal nerves (d) Autonomic nerves
94. How many pairs of cranial nerves in mammals are purely sensory
 (a) Five (b) Four
 (c) Three (d) Two
95. Third ventricle of rabbit's brain is called [CBSE PMT 1990]
 (a) Rhinocoel (b) Rhombocoel
 (c) Diocoel (d) None of these
96. Which of the following is a richly vascular layer with lots of blood capillaries
 (a) Duramater of brain (b) Piamater of spinal cord
 (c) Epidermis of skin (d) Epithelial lining of trachea
97. The following cranial nerve plays an important role in regulating heart beat
 (a) IX (b) VII
 (c) X (d) VIII
98. That part of the brain which is involved in interpreting an input, storing input information and initiating a response in the light of similar past experience is [Kerala PMT 2004]
 (a) Motor area (b) Sensory area
 (c) Association area (d) Pons
 (e) Cerebellum
99. Pioneer work on conditioned reflex was done by [CPMT 1996]
 (a) Kärner (b) Pavlov
 (c) Darwin (d) Lamarck
100. Tongue is under control of [CPMT 2004; WB JEE 2011]
 (a) Trigeminal nerve
 (b) Facial nerve
 (c) Automatic nervous system
 (d) Glossopharyngeal nerve
101. Each spinal nerve in a mammal arises from the spinal cord by two roots, a dorsal and a ventral. Of these the ventral root is composed of [Pb. PMT 1999]
 (a) Somatic motor and visceral motor fibres
 (b) Somatic sensory and visceral motor fibres
 (c) Somatic motor and visceral sensory fibres
 (d) Somatic sensory and visceral sensory fibres
102. Dorsal root ganglion are [CPMT 1993]
 (a) Mixed (b) Motor
 (c) Sensory (d) None of these
103. The cytons of reflex in central nervous system and autonomic nervous system is [CPMT 1993]
 (a) Sensory (b) Mixed
 (c) Motor (d) All of these
104. Myelin sheath covers [MP PMT 2004]
 (a) Muscle fibre (b) Nerve fibre
 (c) Collagen fibre (d) Tendon
105. Reflex action in a vertebrate is an essential display exhibited by [MP PMT 1994]
 (a) Sympathetic nerve (b) Motor nerve
 (c) Sensory nerve (d) Autonomic response
106. Cerebral hemisphere is the centre of [MP PMT 1994]
 (a) Thinking (b) Will power
 (c) Reasoning (d) All of these
107. Dicondylic skull and 10 pairs of cranial nerves are found in [RPMT 1999; CPMT 2005]
 (a) Reptilia (b) Aves
 (c) Amphibia (d) All
108. Lateral ventricles are found in [MP PMT 1995]
 (a) Heart (b) Brain
 (c) Thyroid (d) Brain and heart
109. Medulla oblongata controls [RPMT 1999; CPMT 2002; MP PMT 2010, 11]
 (a) Blood pressure (b) Ventilation
 (c) Breathing (Respiration) (d) All of these
110. In after cutting through the dorsal root of a spinal nerve of a mammal, an associated receptor in the skin were stimulated, the animal would [CPMT 2005]
 (a) Still be able to feel the stimulation
 (b) Show no response
 (c) Show a normal but slow response
 (d) Respond but only at a different level of spinal cord
111. 9th pair of cranial nerve in frog is [AFMC 2005]
 (a) Hypoglossal (b) Glossopharyngeal
 (c) Vagus (d) Trigeminal

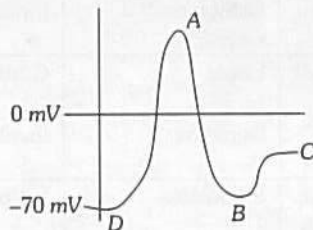
112. Which of the following part of a neuron is covered by fatty sheath
[BHU 2004; AMU (Med.) 2005]
- Or**
- The efferent process of neuron is known as [KCET 1999]
- (a) Axon (b) Cyton
(c) Dendrite (d) Node of Ranvier
113. Injury to vagus nerve in humans is not likely to affect
[CBSE PMT 2004]
- (a) Pancreatic secretion
(b) Cardiac movements
(c) Tongue movements
(d) Gastrointestinal movements
114. Choroid plexus is a network of [KCET 2004]
- (a) Capillaries (b) Muscle fibres
(c) Nerves (d) Lymph vessels
115. Nissl's granules are absent in [CPMT 2001; DPMT 2004]
- (a) Axon (b) Cyton
(c) Dendron (d) Both 'a' and 'b'
116. Broca's area is situated in [WB JEE 2008]
- (a) Frontal lobe (b) Parietal lobe
(c) Temporal lobe (d) Occipital lobe
117. Function of sympathetic nervous system is to
[CPMT 1994; CBSE PMT 1999; RPMT 2006]
- (a) Decrease heart beat (b) Increase heart beat
(c) Contract respiratory organ (d) Secrete saliva
118. The 3rd, 6th and 11th cranial nerves are
[BHU 1995; AFMC 2000; Pb. PMT 2000; CPMT 2001]
- (a) Oculomotor, trigeminal, spinal
(b) Optic, facial, spinal
(c) Oculomotor, abducens, spinal
(d) Trichlear, abducens, vagus
119. Which of the following connect lateral ventricle of diocoel in brain with third ventricle
[BHU 1995; Pb. PMT 1999; MP PMT 2003; Odisha JEE 2010]
- (a) Iter (b) Foramen of Monro
(c) Corpus striatum (d) Filum terminale
120. Sub-arachnoid space is found in [RPMT 1995]
- Or**
- The arachnoid membrane covers the [MP PMT 2000]
- (a) Piamater (b) Durameter
(c) Blastocoel (d) None of the above
121. The primary visual area is located in [KCET 2004]
- (a) Temporal lobe (b) Occipital lobe
(c) Frontal lobe (d) Parietal lobe
122. If the sympathetic nerve to the heart is cut-off, the heart beat will [MP PMT 1998]
- (a) Increase (b) Decrease
(c) Remains same (d) Stop
123. The cranial nerves which control eye-ball movement are [EAMCET 1998; CPMT 2000]
- (a) 4, 6 and 7 (b) 3, 4 and 6
(c) 2, 3 and 5 (d) 5, 8 and 9
124. Conditioned reflexes are different than unconditioned reflexes in that [CPMT 1998]
- (a) Conditioned reflexes are limited to brain
(b) Unconditioned reflexes are limited to brain
(c) Both (a) and (b)
(d) None of the above
125. Nodes of Ranvier are found in [MP PMT 2000; KCET 2004; BVP 2004]
- (a) Axon (b) Sperm
(c) Muscle fibre (d) Neuron
126. Cerebrum is a part of [WB JEE 2016]
- (a) Mesencephalon (b) Metencephalon
(c) Prosencephalon (d) Myelencephalon
127. Which one of the following cranial nerves is a parasympathetic nerve [WB JEE 2016]
- (a) Facial (b) Auditory
(c) Abducens (d) Vagus

Biochemical aspect of nervous physiology

1. Reflex arc consists of [Odisha JEE 2008]
- (a) Motor nerve
(b) Sensory nerve
(c) Both sensory and motor nerves
(d) None of these
2. Given below is a table comparing the effects of sympathetic and parasympathetic nervous system for four features (a-d). which one feature is correctly described [AIIMS 2008, 13]
- | | Feature | Sympathetic Nervous system | Parasympathetic Nervous System |
|-----|------------------------|----------------------------|--------------------------------|
| (a) | Salivary gland | Stimulates secretion | Inhibits secretion |
| (b) | Pupil of the eye | Dilate | Constricts |
| (c) | Heart rate | Decreases | Increases |
| (d) | Intestinal peristalsis | Stimulates | Inhibits |
3. Preparation of the type of stimulus depends on the [AIIMS 1992]
- (a) Strength of the nerve impulse
(b) Specificity of connection to receptor organs
(c) Rate of the nerve impulse
(d) Ionic change moving in and out of the nerve
4. The following hormones are neurotransmitters [CBSE PMT 1992; Bihar CECE 2006; MP PMT 2013]
- (a) Acetylcholine and secretin
(b) Cholecystokinin and acetylcholine
(c) Adrenalin and acetylcholine
(d) Cholecystokinin and adrenalin
5. Which of the following is not an effect of the sympathetic nervous system [AMU (Med.) 2010]
- (a) Dilation of pupil
(b) Inhibition of peristalsis
(c) Elevation of blood pressure
(d) Stimulation for saliva secretion

980 Neural Control and Coordination

6. During the transmission of nerve impulse, which of the following takes place [MP PMT 2002]
- Flux of Na^+ inwards and K^+ outwards
 - Flux of K^+ inwards and Na^+ outwards
 - Flux of K^+ inwards and Na^+ inwards
 - Flux of K^+ outwards and Na^+ outwards
7. During the propagation of a nerve impulse, the action potential results from the movement of [CBSE PMT 2008]
- K^+ ions from intracellular fluid to extracellular fluid
 - Na^+ ions from extracellular fluid to intracellular fluid
 - K^+ ions from extracellular fluid to intracellular fluid
 - Na^+ ions from intracellular fluid to extracellular fluid
8. How many pairs of cranial nerves originate from the brain of rat [Kerala PMT 2008]
- 12
 - 8
 - 9
 - 11
 - 10
9. The potential maintained across the neuron membrane during the resting state is [Kerala PMT 2008; AIIMS 2009]
- + 70 mV
 - 70 mV
 - 0.5 V
 - 30 mV
 - + 30 mV
10. The cutaneous plexus and the papillary plexus consist of [DUMET 2009]
- A network of nerves to provide dermal sensation
 - A network of arteries to provide dermal supply
 - Specialized cells for cutaneous sensations
 - Gland cells that release cutaneous secretions
- 11.



Identify the region where all Na^+ channels are reactivated but closed and all K^+ channels are closed [EAMCET 2009]

- D
 - C
 - B
 - A
12. Which one of the following does not act as a neurotransmitter [CBSE PMT 2006; WB JEE 2009]
- Norepinephrine
 - Cortisone/Tyrosine
 - Acetylcholine
 - Epinephrine
13. The chemical causing the transmission of nerve impulse across synapses is [KCET 1994;

BHU 1999, 2008; CBSE PMT 2000; AFMC 2001, 08; DPMT 2003; BVP 2004; CPMT 2009]

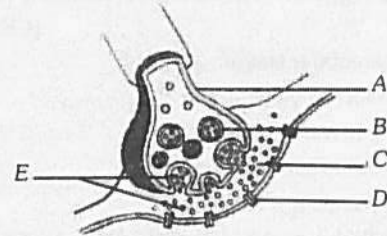
Or

The neurotransmitter which communicates between two neurons or between a neuron and a muscle is

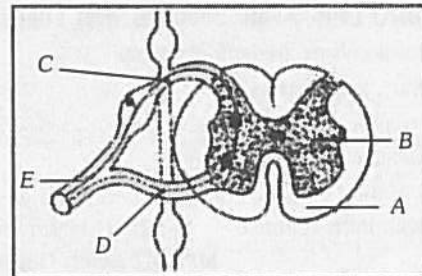
[MP PMT 1993, 95; BHU 1995; DPMT 2004; WB JEE 2016]

- Acetylcholine
- Cholinesterase
- Choline
- Acetic acid

14. The action potential of a nerve cell is
- 45 mV
 - 55 mV
 - 80 mV
 - 75 mV
15. In the following diagram showing axon terminal and synapse, A, B, C, D and E respectively represents [Kerala PMT 2010; NEET 2013; NEET (Karnataka) 2013]



- Axon terminal, synaptic cleft, synaptic vesicles, neurotransmitters and receptors
 - Axon terminal, synaptic vesicles, synaptic cleft, receptors and neurotransmitters
 - Synaptic cleft, synaptic vesicles, axon terminal, neurotransmitters and receptors
 - Synaptic cleft, axon terminal, synaptic vesicles, neurotransmitters and receptors
 - Synaptic vesicles, axon terminal, synaptic cleft, receptors and neurotransmitters
16. In a cross section of the spinal cord A, B, C, D and E represents [Kerala PMT 2009]



- A - white matter, B - grey matter, C - dorsal root, D - ventral root, E - spinal nerve
 - A - white matter, B - grey matter, C - ventral root, D - dorsal root, E - spinal nerve
 - A - grey matter, B - white matter, C - ventral root, D - dorsal root, E - spinal nerve
 - A - grey matter, B - white matter, C - dorsal root, D - ventral root, E - spinal nerve
 - A - white matter, B - grey matter, C - spinal nerve, D - ventral root, E - dorsal root
17. The blood-brain barrier [J & K CET 2012]
- Consists of both anatomical and physiological factors
 - Regulates to some extent the passage of substances from the blood to the interstitial fluid of the brain
 - Is anatomically related to the formation of tight junctions between adjacent capillary endothelial cells
 - All of the above are correct

18. During synaptic transmission of nerve impulse, neurotransmitter (p) is released from synaptic vesicles by the action of ions (Q). Choose the correct P and Q

[WB JEE 2012]

- (a) P = acetylcholine, Q = Ca^{++}
- (b) P = acetylcholine, Q = Na^+
- (c) P = GABA, Q = Na^+
- (d) P = cholinesterase, Q = Ca^{++}

19. An investigator places an isolated neuron in a calcium free medium, gives the neuron a suprathreshold stimulus and then performs an assay to test whether neurotransmitter is released into the medium. Which of the following outcomes would you predict

[J & K CET 2012]

- (a) No neurotransmitter is detected since influx of calcium into the synaptic knob is required for neurotransmitter release
- (b) No neurotransmitter is detected since influx of calcium is required in order for the neuron to conduct an action potential
- (c) Neurotransmitter is detected since calcium is not required for action potential conduction and the initial stimulus was suprathreshold
- (d) We cannot predict the outcome without knowing whether the neuron was myelinated

20. Which option is correct for the correctly matched groups for the column I, column II and column III

[GUJCET 2014]

	Column I	Column II	Column III
(a)	Resting membrane potential	i. Na^+ channel get open	e. Na^+ and K^+ pumps are responsible for it
(b)	Action potential	ii. Na^+ channel is closed	f. Last for very short time
(c)	Depolarization	iii. Na^+ ions are more on outer side	g. K^+ ions move on outside of membrane
(d)	Repolarization	iv. Na^+ ions are more on inner side of membrane	h. Positive charge on inner side of membrane

- (a) (a - ii - h) (b - i - g) (c - iii - e) (d - iv - f)
- (b) (a - iii - e) (b - iv - f) (c - i - h) (d - ii - g)
- (c) (a - iv - f) (b - iii - e) (c - i - e) (d - ii - h)
- (d) (a - iv - e) (b - iii - f) (c - ii - g) (d - i - g)

21. The release of chemical messenger from synaptic vesicles is under the influence of these ion(s)

[AIIMS 2012]

- (a) Cl^-
- (b) Fe^{+} and S^{++}
- (c) Ca^{++}
- (d) Mg^{++} and Sr^{++}

22. The potential difference between outside and inside of a nerve before excitation is known as

[MP PMT 1996; Kerala PMT 2010]

- (a) Resting potential
- (b) Action potential
- (c) Spike potential
- (d) Reaction potential

23. Depolarization of a stimulated nerve is maintained by

[MP PMT 1996]

- (a) Ca^{++}
- (b) Cl^-
- (c) Mg^{++}
- (d) K^+

24. During transmission of nerve impulse the potential inside membrane has the following type of charge

[CBSE PMT 2007]

- (a) First positive, then negative and back positive
- (b) First negative then positive and back negative
- (c) First positive then negative and remain negative
- (d) First negative then positive and remain positive

25. Nerve gas affects neuromuscular activity by

[BHU 2012]

- (a) Blocking the acetylcholine receptor sites
- (b) Inhibiting the release of acetylcholine
- (c) Inhibiting acetylcholinesterase
- (d) Enhancing the release of acetylcholine

26. Destruction of the anterior horn cell of the spinal cord would result in loss of

[AIPMT 2015]

- (a) Voluntary motor impulses
- (b) Commissural impulses
- (c) Integrating impulses
- (d) Sensory impulses

27. Which of the following is not a type of neuroglial cells

[Odisha JEE 2012]

- (a) Astrocytes
- (b) Oligodendrocytes
- (c) Microglia
- (d) Chondrocytes

28. Which of the following option is correct for the statement 'X' and 'Y'

Statement 'X' – Immediately after repolarization, ionic imbalance is created on both the sides of the nerve fibre
Statement 'Y' – During repolarization K^+ ion channel open up and K^+ ion moves on innerside of plasma membrane

[GUJCET 2014]

- (a) Statements 'X' and 'Y' are correct and 'Y' is correct for 'X'
- (b) Statements 'X' and 'Y' are correct and 'Y' is not correct for 'X'
- (c) Statement 'X' is correct and 'Y' is wrong
- (d) Statement 'X' is wrong and 'Y' is correct

29. Afferent nerve fibres carry impulses from

[CBSE PMT 1992]

- (a) Effector organs to central nervous system
- (b) Receptors to central nervous system
- (c) Central nervous system to muscles
- (d) Central nervous system to receptors

30. On nerve fibres to prevent leakage of an impulse layer of is found

[CPMT 1993]

- (a) Schwann cells
- (b) Neurilemma
- (c) Axons
- (d) Myelin sheath

31. All sensory pathways to the cerebral cortex synapse at the

[AMU (Med.) 2009]

- (a) Pons
- (b) Hypothalamus
- (c) Thalamus
- (d) Cerebellum

32. These processes occurs during repolarization of nerve fibre

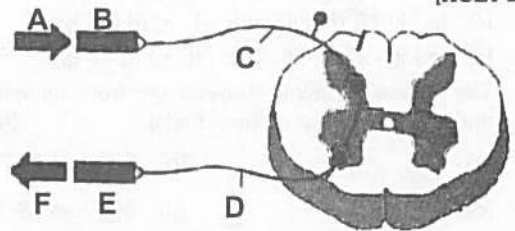
- (i) Open Na^+ channel
- (ii) Closed Na^+ channel
- (iii) Closed K^+ channel
- (iv) Open K^+ channel

[GUJCET 2007; DPMT 2007]

- (a) (ii) and (iv)
- (b) (i) and (iii)
- (c) (ii) and (iii)
- (d) (i) and (ii)

982 Neural Control and Coordination

33. Which of the following is not a reflex action [BHU 2012]
 (a) Blinking of eyes
 (b) Salivation
 (c) Sweating
 (d) Withdrawal of hand on touching some hot object
34. Nerve impulse travels faster in [CPMT 1994; AFMC 2008]
 (a) Medullated nerve (b) Non-medullated nerve
 (c) Cranial nerve (d) Spinal nerve
35. The amount of CSF in the cranial cavity is [WB JEE 2011]
 (a) 500 ml (b) 140 ml
 (c) 1 litre (d) 1.5 ml
36. Synaptic vesicle is found in [DPMT 2007]
 (a) Pre-synaptic neuron (b) Post synaptic neuron
 (c) Synaptic left (d) None of these
37. Nerve impulse initiates with the movements of [BHU 1999; MH CET 2001; MP PMT 2003; RPMT 2006]
Or
 Neuron becomes an electrically charged cell by the diffusion of [CPMT 1994; MP PMT 2006]
 (a) K^+ (b) Mg^+
 (c) Ca^+ (d) Na^+
38. Sodium- potassium pump is [RPMT 2001]
 (a) A hormone (b) An enzyme
 (c) A protein carrier (d) An organelle
39. For visual sense, the nerve impulse is generated by [RPMT 2001]
 (a) Depolarisation
 (b) Repolarisation
 (c) Hyper polarisation
 (d) Depolarisation and repolarisation
40. The enzyme required for the conduction of nerve impulses across synapse is [CBSE PMT 2001]
 (a) Peroxidase (b) Choline acetylase
 (c) Ascorbic acid oxidase (d) Succinic dehydrogenase
41. Unidirectional transmission of a nerve impulse through nerve fibre is due to the fact that [AIIMS 2004]
 (a) Nerve fibre is insulated by a medullary sheath
 (b) Sodium pump starts operating only at the cyton and then continues into the nerve fibre
 (c) Neurotransmitters are released by dendrites and not by axon endings
 (d) Neurotransmitters are released by the axon endings and not by dendrites
42. Cerebrospinal fluid is present [Kerala PMT 2004]
 (a) Beneath the piamater
 (b) Between piamater and arachnoid mater
 (c) Between arachnoid and duramater
 (d) In extra duramater
 (e) Between the duramater and cranium
43. Intercellular communication in multicellular organism occurs through [BHU 2000; CPMT 2004]
 (a) Digestive system only
 (b) Respiratory system only
 (c) Nervous system only
 (d) Both nervous and endocrine system
44. Which of the following substances leads to the inhibition of central nervous system [CPMT 2004]
 (a) Glycine (b) GABA
 (c) Nor epinephrine (d) Both 'a' and 'b'
45. Transmission of nerve impulse, across the synapse is accomplished by [Pb. PMT 2004]
 (a) Release of ions
 (b) Release of neurotransmitters
 (c) Movement of water
 (d) Movement of Na^+ and K^+
46. The brain stem is made up of [KCET 2011]
 (a) Midbrain, pons, cerebellum
 (b) Midbrain, pons, medulla oblongata
 (c) Diencephalon, medulla oblongata, cerebellum
 (d) Cerebellum, cerebrum, medulla oblongata
47. Parkinson's disease (characterized by tremors and progressive rigidity of limbs) is cause by degeneration of brain neurons that are involved in movement control and make use of neurotransmitter [CBSE PMT 2005; WB JEE 2011]
 (a) Acetylcholine (b) Nor epinephrine
 (c) Dopamine (d) GABA
48. One of the example of the action of the autonomous nervous system is [CBSE PMT 2005]
 (a) Knee-jerk response (b) Pupillary reflex
 (c) Swallowing of food (d) Peristalsis of the intestines
49. In parasympathetic nervous system which of the following is released [BHU 2005]
 (a) Epinephrine (b) Nor epinephrine
 (c) Serotonin (d) Acetylcholine
50. The following is the scheme showing the path of reflex arc. Identify the different labellings A, B, C, D, E, F in the reflex arc [KCET 2010]



- | | A | B | C | D | E | F |
|-----|----------|----------|---------------|---------------|----------|----------|
| (a) | Stimulus | Effector | Sensory nerve | Motor nerve | Receptor | Response |
| (b) | Stimulus | Receptor | Sensory nerve | Motor nerve | Effector | Response |
| (c) | Stimulus | Effector | Motor nerve | Sensory nerve | Receptor | Response |
| (d) | Stimulus | Receptor | Motor nerve | Sensory nerve | Effector | Response |

51. Hypothalamus does not control
[NCERT; Kerala CET 2005; WB JEE 2010]
- Hunger and satiety
 - Thermoregulation
 - Libido
 - Creative thinking and consciousness
 - Osmoregulation

52. You are watching a horror movie and you notice that your heart is beating fast and mouth is dry. It is because of
[Kerala CET 2005]
- Fight and flight response
 - Autonomic nervous system
 - Sympathetic nervous system
 - Both (a) and (c)
 - Parasympathetic nervous system

53. Which one of the following reflex do not include innervation of brain
[Odisha JEE 2005]
- Spinal reflex
 - Cranial reflex
 - Afferent reflex
 - Efferent reflex

54. Which of the statements about the mechanism of muscle contraction are correct
- Acetylcholine is released when the neural signal reaches the motor end plate
 - Muscle contraction is initiated by a signal sent by CNS via a sensory neuron
 - During muscle contraction, isotropic band gets elongated
 - Repeated activation of the muscles can lead to lactic acid accumulation

[Kerala PMT 2011]

- I and IV are correct
- I and III are correct
- II and III are correct
- I, II and III are correct
- I and II are correct

55. In a modulated nerve fibre, the conduction of impulse is faster due to the presence of
[Odisha JEE 2010]

- Pericytes
- Endoneurium and epineurium
- Myelin sheath and nodes of Ranvier
- Nissl's granules

56. When a neuron is in resting state i.e. not conducting any impulses, the axonal membrane is [CBSE PMT (Pre.) 2011]

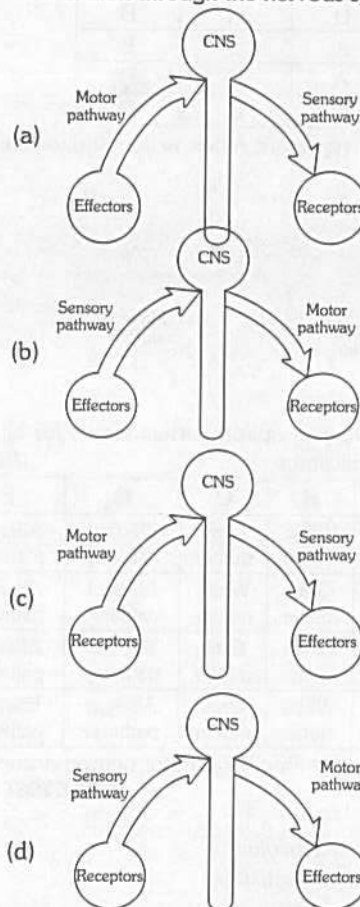
- Comparatively more permeable to K^+ ions and nearly impermeable to Na^+ ions
- Comparatively more permeable to Na^+ ions and nearly impermeable to K^+ ions
- Equally permeable to both Na^+ and K^+ ions
- Impermeable to both Na^+ and K^+ ions

57. Which of the following statements are correct and incorrect
- Synaptic cleft of neurons secrete adrenaline
 - Myelinated nerve fibres are enveloped with Schwann cells, which form a myelin sheath around the axon
 - Non-myelinated nerve fibre is enclosed by a Schwann cell that does not form a myelin sheath
 - Spinal cord and cranial nerves are made of non-myelinated nerve fibres of the four statements

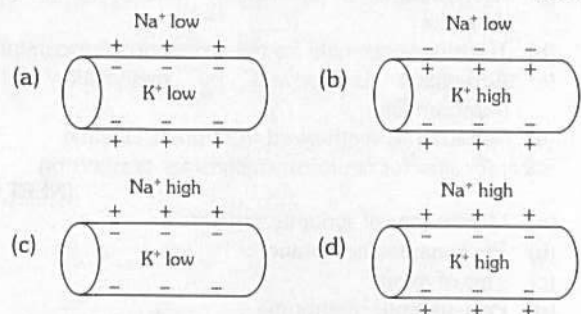
[Kerala PMT 2011]

- 1, 2 are correct but 3 and 4 are incorrect
- 1, 2 and 3 are correct but 4 is incorrect
- 3 and 4 are correct but 1 and 2 are incorrect
- 1 and 4 are correct while 2 and 3 are incorrect
- 2 and 3 are correct while 1 and 4 are incorrect

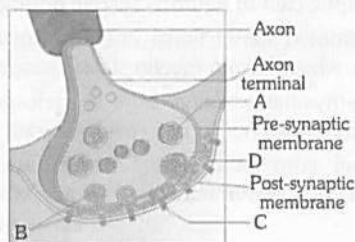
58. Choose the correct diagram which represent the flow of information through the nervous system [NCERT]



59. Which diagram shows the distribution of Na^+ and K^+ ions in a section of non-myelinated axon which is at resting potential [NCERT]



60. Consider the diagram of synapse

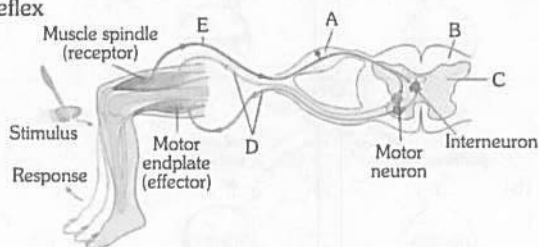


- I. The numbered label indicate the location of the receptor molecules
- II. The number points to a synaptic vesicles
- III. The number points to neurotransmitter
- IV. The number points to synaptic cleft

[NCERT]

	I	II	III	IV
(a)	C	D	A	B
(b)	C	A	D	B
(c)	B	A	C	D
(d)	C	A	B	D

61. The given diagram represent reflex action shows knee jerk reflex



In which of the following option correct words for all the 5 blanks (A to E) are illustrate [NCERT]

	A	B	C	D	E
(a)	Ventral root ganglion	White matter	Gray matter	Efferent pathway	Afferent pathway
(b)	Dorsal root ganglion	Gray matter	White matter	Efferent pathway	Afferent pathway
(c)	Dorsal root ganglion	White matter	Gray matter	Efferent pathway	Afferent pathway
(d)	Dorsal root ganglion	White matter	Gray matter	Afferent pathway	Efferent pathway

62. Stimulation of a muscle fibre by a motor neuron occurs at [CBSE PMT 2014]

- (a) The myofibril
 - (b) The sarcoplasmic reticulum
 - (c) The neuromuscular junction
 - (d) The transverse tubules
63. Select the correct combination of statements for the neurotransmitters [WB JEE 2016]
- (a) Acetylcholine is inactivated mainly by presynaptic reuptake
 - (b) Tyrosine is essential for the formation of dopamine
 - (c) Adrenaline is formed by methylation of the noradrenaline
 - (d) Serotonin is synthesized from phenylalanine
64. Receptor sites for neurotransmitters are presents on [NEET 2017]
- (a) Membranes of synaptic vesicles
 - (b) Pre-synaptic membrane
 - (c) Tips of axons
 - (d) Post-synaptic membrane

65. Myelin sheath is produced by [NEET 2017]

Or

Myelin of the nerve fibres of the central nervous system is produced and maintained by [AMU (Med.) 2009]

- (a) Schwann cell and Oligodendrocytes
- (b) Astrocytes and Schwann cells
- (c) Oligodendrocytes and Osteoclasts
- (d) Osteoclasts and Astrocytes

Different types of Receptors

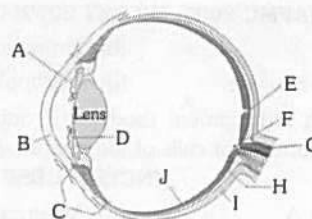
1. The pacinian corpuscle present in the skin is for [DPMT 1993; MH CET 2006; AMU (Med.) 2010]
 - (a) Pain
 - (b) Pressure
 - (c) Movement
 - (d) Temperature
2. Colour blindness results from [MP PMT 1996; AFMC 1997; WB JEE 2010]
 - (a) Absence of rods
 - (b) Absence of cones
 - (c) Absence of eyelids
 - (d) Inverted retina
3. In fishes the lateral line receptors are neuromast organs. These are [AFMC 2006]
 - (a) Olfactoreceptors
 - (b) Gustatoreceptors
 - (c) Rheoreceptors
 - (d) Chemoreceptors
4. Jacobson's organ is concerned with [CPMT 1994; Kerala PMT 2004; MH CET 2006; WB JEE 2010]
 - (a) Smell
 - (b) Burrowing
 - (c) Touch
 - (d) Sight
 - (e) Chemoreception
5. Jacobson's organ in man [MP PMT 1995; AFMC 2001]
 - (a) Functions as smelling organs
 - (b) Functions as gustatory organ
 - (c) Is a vestigeal organ
 - (d) Functions as pain sensory organ
6. Sonar system is found only in [MP PMT 2000]
 - (a) Bats
 - (b) Whales
 - (c) Bats and whales
 - (d) Otter
7. Osphradium of *Pila globosa* is [APMEE 1999; CBSE PMT 2000; BHU 2000, 01; CPMT 2001; DPMT 2004]
 - (a) Photoreceptor
 - (b) Chemoreceptor
 - (c) Thermoreceptor
 - (d) Tangoreceptor
8. Meissner's corpuscles are located in [CPMT 1992, 2002; AIIMS 1993]
 - (a) Pancreas and secrete trypsinogen
 - (b) Adrenal and secrete epinephrin
 - (c) Spleen and destroy worn out erythrocytes
 - (d) Skin and perceive gentle pressure
9. Vibrissae are associated with the function of [JIPMER 1993]
 - (a) Thermoregulation
 - (b) Gustation
 - (c) Tactile perception
 - (d) Reproduction
10. Sensation of stomach pain is due to [AIIMS 1998]
 - (a) Interoceptors
 - (b) Exteroceptors
 - (c) Proprioceptors
 - (d) Teloreceptors
11. The sweet and acidic tastes are better detected by
 - (a) Tip of the tongue
 - (b) Base of the tongue
 - (c) Middle of the tongue
 - (d) Lateral sides of the tongue
12. Proprioceptors are those, which give the sense of [MP PMT 2001; CBSE PMT 2001]
 - (a) Chemicals
 - (b) Temperature
 - (c) Taste
 - (d) Changes in the internal environment of the body

13. Sea gulls excrete excess of NaCl from [BHU 2005]
 (a) Liver (b) Lungs
 (c) Nasal cavity (d) Kidney
14. Animals which have well developed echolocation system like that of bats [KCET 1994; Kerala CET 2002; CPMT 2003; Kerala PMT 2004; J & K CET 2008]
 (a) Wild cats (b) Beavers
 (c) Primates (d) Whales and dolphins
 (e) Hedgehogs
15. The receptors found in the muscles, tendons and joints are [MP PMT 1996, 2002]
 (a) Teloreceptors (b) Proprioceptors
 (c) Interoceptors (d) None of these

Eye

1. Which part of the eye controls the amount of light entering in it [MP PMT 1992; CPMT 1993; DPMT 1993]
Or
 The black pigment in the eye which reduces the internal reflection is located in [AIIMS 1998]
 (a) Cornea (b) Ciliary body
 (c) Iris (d) Suspensory ligament
2. Which of the following prevents internal reflection of light within the eye [RPMT 2005]
Or
 Coloured (Pigmented) layer of eye is [RPMT 1995]
 (a) Cornea (b) Choroid
 (c) Sclera (d) Conjunctiva
3. In the chemistry of vision in mammals, the photosensitive substance is called [CBSE PMT 1997]
Or
 The visual pigment in rods of retina of vertebrate eye which is responsible for detection of light is
Or
 It is present in rods and useful in night vision [GUJCET 2007]
 (a) Sclerotin (b) Retinol
 (c) Rhodopsin (d) Melanin
4. In mammalian eye, the 'fovea' is the centre of the visual field, where [BHU 2003; AIPMT 2015; WB JEE 2016]
 (a) The optic nerve leaves the eye
 (b) Only rods are present
 (c) More rods than cones are found
 (d) High density of cones occur, but has no rods
5. Which one of the following is correct pairing of a body part and the kind of muscle tissue that moves it [CBSE PMT 2009]
 (a) Heart wall – involuntary unstriated muscle
 (b) Biceps of upper arm – Smooth muscle fibres upper arm
 (c) Abdominal wall – Smooth muscle
 (d) Iris – Involuntary smooth muscle
6. In the following abnormalities of the eye which one is a serious condition that leads to blindness [Kerala CET 2003]
 (a) Presbyopia (b) Myopia
 (c) Hypermetropia (d) Glaucoma

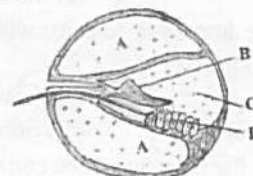7. Study the following figure



- I. Carries nerve signals to the brain
 II. Regulates the size of the pupil to let more or less light into the eye
 III. Changes the shape of the lens
 IV. Photoreceptors are highly concentrated at this center of focus

The correct match of the above functions with parts of the eye indicated by letters is [NCERT]

- (a) I - G, II - D, III - C, IV - E (b) I - A, II - C, III - E, IV - G
 (c) I - J, II - G, III - F, IV - C (d) I - B, II - D, III - F, IV - H
8. Given below is a diagrammatic cross section of a single loop of human cochlea

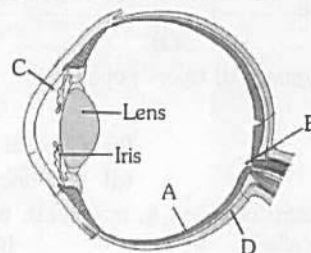


[CBSE PMT 2008; AIIMS 2012]

- Which one of the following options correctly represents the names of three different parts
 (a) D : Sensory hair cells, A : Endolymph, B : Tectorial membrane
 (b) A : Perilymph, B : Tectorial membrane, C : Endolymph
 (c) B : Tectorial membrane, C : Perilymph, D : Secretory cells
 (d) C : Endolymph, D : Sensory hair cells, A : Serum
9. In the blind spot where the optic nerves leave the eye [NCERT; AFMC 2006]
 (a) Rods and cones are absent
 (b) Only cones are present
 (c) Only rods are present
 (d) Special neurons are present
10. Dark adaptation in human eye involves [AMU (Med.) 2012]
 (a) Conversion of 11 *cis* retinene to *trans* retinene
 (b) Conversion of *trans* retinene into 11 *cis* retinene
 (c) Decomposition of rhodopsin into retinene
 (d) Decomposition of rhodopsin to scotopsin
11. Cavity of vitreous humour in the eyes are situated [AIIMS 1993]
 (a) Behind the lens
 (b) Infront of the lens
 (c) Behind the retina
 (d) Between the retina and sclerotic

986 Neural Control and Coordination

12. The rods and cones of the eye retinal layer are modified
[AFMC 2005; MP PMT 2009; Odisha JEE 2012]
(a) Hair (b) Unipolar neurons
(c) Bipolar neurons (d) Multipolar neurons
13. The purplish red pigment rhodopsin contained in the rods type of photoreceptor cells of the human eye, is a derivative of
[NCERT; CBSE PMT (Pre.) 2011]
(a) Vitamin A (b) Vitamin B₁
(c) Vitamin C (d) Vitamin D
14. Iodopsin is a light sensitive (photosensitive) pigment and is present in the
[CPMT 1992, 93; Bihar CECE 2006; AFMC 2010; DUMET 2010]
(a) Rods (b) Cones
(c) Neuroglia (d) Bipolar cells
15. Retina is most sensitive at [AFMC 1997; MHCET 2002]
(a) Optic disc (b) Periphery
(c) Macula lutea (d) Fovea centralis
16. Which function will be lost due to damage of occipital lobe
[MH CET 2007; WB JEE 2011]
(a) Hearing (b) Speech
(c) Vision (d) Memory
17. UV radiation from sun causes which of the following disorder of eyes
[BHU 2004]
(a) Cataract (b) Glaucoma
(c) Dilation pupil (d) Some defect of retina
18. Which one of the following is the correct difference between Rod Cells and Cone Cells of our retina [CBSE PMT 2008]
- | | Rod Cells | Cone Cells |
|------------------------------|---------------------------------------|---|
| (a) Overall function | Vision in poor light | Colour vision and detailed vision in bright light |
| (b) Distribution | More concentrated in centre of retina | Evenly distributed all over retina |
| (c) Visual acuity | High | Low |
| (d) Visual pigment contained | Iodopsin | Rhodopsin |
19. Cornea transplant in humans is almost never rejected. Because [CBSE PMT 1996, 2008]
(a) It is composed of enucleated cells
(b) It is a non-living layer
(c) Its cells are least penetrable by bacteria
(d) It has no blood supply
20. The function of iris in the eyes of frog is to [BHU 1999]
(a) Refraction of light rays
(b) Alter the size of the pupil
(c) Move the nictitating membrane
(d) Move the lens forward and backward
21. Fovea in the eye is a central pit in the yellowish pigmented spot called [Kerala PMT 2008]
(a) Blind spot (b) Retina
(c) Cornea (d) Macula lutea
(e) Choroid
22. Iris of an eye is an extension of [NCERT]
(a) Cornea (b) Sclerotic
(c) Retina (d) Both choroid and retina
23. Acute vision is found in
(a) Vulture (b) Frog
(c) Shark (d) Bat
24. The optic lobes in humans are represented by the corpora [NCERT; AMU (Med.) 2010, 12]
(a) Bigemina (b) Arenacea
(c) Striata (d) Quadrigemina
25. Sensory neurons of retina of eye are [Odisha JEE 2009]
(a) Rods and cones
(b) Maculae and cristae
(c) Pacinian and Ruffini's corpuscles
(d) All of these
26. The decoding and interpretation of visual information is carried out by which part of the brain [Kerala PMT 2006]
(a) Cerebellum (b) Frontal lobe
(c) Parietal lobe (d) Temporal lobe
(e) Occipital lobe
27. Parts A, B, C and D of the human eye are shown in the diagram. Select the option which gives correct identification along with its functions/ characteristics



- [NEET 2013]
(a) D – Choroid – its anterior part forms ciliary body
(b) A – Retina – contains photo receptors-rods and cones
(c) B – Blind spot – has only a few rods and cones
(d) C – Aqueous chamber reflects the light which does not pass through the lens
28. Protein found in eye lens is [DPMT 2007]
(a) Crystallin (b) Collagen
(c) Opsin (d) Rhodopsin
29. The size of pupil is controlled by the [NCERT; DUMET 2009]
(a) Ciliary muscles (b) Suspensory ligaments
(c) Cornea (d) Iris muscles
30. Match the following
- | Column I | Column II |
|-----------------|---|
| (A) Fovea | (1) Provides opening for entry of light |
| (B) Iris | (2) Transduces RGB light |
| (C) Pupil | (3) Transmits information to CNS |
| (D) Lens | (4) Controls amount of light entering |
| (E) Optic nerve | (5) Focuses light on the retina |
- [NCERT; Kerala PMT 2009]
(a) (A) — (4), (B) — (1), (C) — (5), (D) — (2), (E) — (3)
(b) (A) — (5), (B) — (1), (C) — (4), (D) — (3), (E) — (2)
(c) (A) — (3), (B) — (1), (C) — (4), (D) — (5), (E) — (2)
(d) (A) — (1), (B) — (2), (C) — (3), (D) — (4), (E) — (5)
(e) (A) — (2), (B) — (4), (C) — (1), (D) — (5), (E) — (3)

- 31.** The muscles surrounding the pupil of rabbit's eye are [CPMT 2004]
 (a) Unstriated and involuntary (b) Striated and voluntary
 (c) Unstriated and voluntary (d) Striated and involuntary
- 32.** In human beings the total visual field and the stereoscopic visual field respectively is [AMU (Med.) 2009]
 (a) 180° and 140° (b) 140° and 26°
 (c) 180° and 26° (d) 140° and 52°
- 33.** The innermost layer of the human eye is [Kerala PMT 2010]
 (a) Choroid (b) Cornea
 (c) Sclera (d) Retina
 (e) Lens
- 34.** The iris of eye is [RPMT 1999]
 (a) Photosensitive (b) Chemoreceptor
 (c) Calororeceptor (d) All
- 35.** The unit of photoreception, in a compound eye of cockroach and other insects, is [Pb. PMT 1999]
 (a) Ctenidium (b) Osphradium
 (c) Ommatidium (d) Rhabdome
- 36.** In the myopia eye defect, the rays of light [CBSE PMT 2000; AIIMS 2003]
 (a) Do not enter the eye at all
 (b) Come to a focus at back of retina
 (c) Come to a focus in front of the retina
 (d) Come to a focus in between retina & iris
- 37.** Only rods are present in the eyes of one of the following animals [MP PMT 2001]
 (a) Pigeon (b) Squirrel
 (c) Fowl (d) Owl
- 38.** Vitreous humour is seen in [CBSE PMT 1993]
 (a) Ear (b) Eye
 (c) Brain (d) Bone marrow
- 39.** The space between the lens and the cornea of the human eye is [AIIMS 1993]
 (a) Vitreous chamber (b) Aqueous chamber
 (c) Retina (d) Iris
- 40.** Glaucoma is an eye disease arising from [JIPMER 1993, 2002]
 (a) Increased pressure of fluid in eye ball
 (b) Elongation of eye ball
 (c) Shortening of eye ball
 (d) Irregularity in the surface of cornea
- 41.** The movement of eye ball is brought about by the [DPMT 1993]
 (a) Adductor muscle (b) Rectus muscle
 (c) Biceps (d) Peroneus
- 42.** The hollow of the eye is divided into aqueous chamber and vitreous chamber by [DPMT 1993; MP PMT 2007]
 (a) Optic nerve (b) Retina
 (c) Lens (d) Iris
- 43.** The central opening of iris is called as [CBSE PMT 1993]
 (a) Pupil (b) Cornea
 (c) Lens (d) Fovea centralis
- 44.** The human eye is sensitive only to light having wave length ranging from [JIPMER 2002]
 (a) 80 to 280 nanometres (b) 380 to 760 nanometres
 (c) 780 to 870 nanometres (d) 880 to 980 nanometres
- 45.** The number of occipital condyles in man is/are [Kerala PMT 2010]
 (a) One (b) Two
 (c) Three (d) Four
 (e) Five
- 46.** The posterior part of the retina, which is just opposite to the lens is [AIIMS 2009]
 (a) Cornea (b) Yellow spot
 (c) Area centralis (d) Both (b) and (c)
- 47.** In man, the image formation occur on retina for most bright vision it should form on [RPMT 2001]
 (a) At the place of entry of optic nerve
 (b) Blind spot
 (c) Yellow spot
 (d) At the junction of ciliary body and lens
- 48.** Which of the following have "ommatidia" as unit of eye [RPMT 2001]
 (a) *Pheretima* (b) House fly
 (c) *Pila* (d) Sepia
- 49.** Sensitive (pigmented) layer of eye is [NCERT; MP PMT 2006; Odisha JEE 2010]
 (a) Sclerotic (b) Retina
 (c) Cornea (d) None of these
- 50.** The cornea and lens of the mammalian eyes are both
 (a) Richly supplied by nerves
 (b) Richly supplied by blood vessels
 (c) Transparent and they diverge the light rays to form an image on retina
 (d) Transparent and they contribute in the formation of image on retina
- 51.** Lens of eye retina is developed from [CPMT 1998]
 (a) Ectoderm (b) Mesoderm
 (c) Endoderm (d) Ecto-mesoderm
- 52.** Choroid is
 (a) Middle layer of ear (b) Innermost layer of eye
 (c) Innermost layer of ear (d) Middle layer of eye
- 53.** As compared to rods the cones are times less sensitive
 (a) 100 (b) 200
 (c) 300 (d) 400
- 54.** A 22 years student goes to his ophthalmologist. He has problem in reading books because he is not able to contract his [CPMT 2009]
 (a) Suspensory ligament (b) Pupil
 (c) Iris (d) Ciliary muscles
- 55.** The lens and cornea is not having blood supply. So the nutrients are supplied by [Kerala CET 2003]
 (a) Retina (b) Blind spot
 (c) Vitreous body (d) Aqueous humour
- 56.** Photosensitive compound in human eye is made up of [NEET (Phase-I) 2016]
 (a) Guanosine and Retinol (b) Opsin and Retinal
 (c) Opsin and Retinol (d) Transducin and Retinene

988 Neural Control and Coordination

57. Choose the **correct** statement [NEET (Phase-II) 2016]
(a) Receptors do not produce graded potentials
(b) Nociceptors respond to changes in pressure
(c) Meissner's corpuscles are thermoreceptors
(d) Photoreceptors in the human eye are depolarized during darkness and become hyperpolarized in response to the light stimulus
58. Which cell in the retina recognize colour [WB JEE 2016]
(a) Rod cells (b) Cone cells
(c) Both Rod and Cone cells (d) Epithelial cells
- Ear**
1. Hearing in rabbit is better than frog. One reason for this is that rabbit has [MP PMT 1992]
(a) Three semicircular canal
(b) Vibratile tympanic membrane
(c) Movable pinna
(d) Both fenestra ovalis and eustachian tubes
2. Scala vestibuli is connected with [NCERT; MP PMT 1992]
(a) Fenestra rotundus (b) Fenestra ovalis
(c) Scala tympani (d) Scala media
3. Identify the correct sequence of organs/regions in the organization of human ear as an auditory mechanoreceptor organ [NCERT; Kerala PMT 2007]
(a) Pinna – Cochlea – Tympanic membrane – Auditory canal – Malleus – Stapes – Incus – Auditory nerve
(b) Pinna – Tympanic membrane – auditory canal – Incus – Malleus – Stapes – Cochlea – Auditory nerve
(c) Pinna – Malleus – Incus – Stapes – Auditory canal – Tympanic membrane – Cochlea – Auditory nerve
(d) Pinna – Tympanic membrane – Auditory canal – Cochlea – Malleus – Incus – Stapes – Auditory nerve
(e) Pinna – Auditory canal – Tympanic membrane – Malleus – Incus – Stapes – Cochlea – Auditory nerve
4. Statolith is an organ which helps in [DPMT 1993]
(a) Vision (b) Equilibrium
(c) Tactile stimulation (d) Chemical stimulation
5. Acoustic spots in frog is present in [CPMT 2002; RPMT 2005]
(a) Ossious labyrinth (b) Carotid
(c) Membranous labyrinth (d) All of these
6. The tympanic cavity is connected with the pharynx by
(a) Columella (b) Ear ossicles
(c) Eustachian tube (d) Fallopien tubes
7. Our ear can hear the frequency of sound waves [Kerala CET 2003]
(a) 20 to 20,000 cycles/sec
(b) 1000 to 2000 cycles/sec
(c) 5000 to 7000 cycles/sec
(d) 5000 to 10,000 cycles/sec
8. The perception of sound by a mammal involves the stimulation of the mechano receptors located in the internal ear [CPMT 1992]
(a) On the organ of corti
(b) On the Reissner's membrane
(c) In the sacculus
(d) In the semicircular canal
9. The true sense of equilibrium in mammals are situated in the [RPMT 2001]
(a) Malleus (b) Utriculus
(c) Eustachian tubes (d) Semicircular canal
10. The bony labyrinth is filled with [NCERT; DPMT 1993]
(a) Endolymph (b) Synovial fluid
(c) Perilymph (d) Humour
11. Which part is not included in Cochlear duct [GUJCET 2015]
(a) Reissner's membrane (b) Macula of Utricle
(c) Scala Media (d) Tectorial membrane
12. The kind of tissue that forms the supportive structure in our pinna (external sears) is also found in [CBSE PMT 2009]
(a) Vertebrae (b) Nails
(c) Ear ossicles (d) Tip of the nose
13. High frequency sound waves vibrate the basilar membrane [AMU (Med.) 2009; WB JEE 2016]
(a) Near the oval window
(b) Near the helicotrema
(c) In the middle of cochlea
(d) From oval window to helicotrema
14. Eustachian tube connects [NCERT; CPMT 2009]
(a) Pharynx with middle ear
(b) Middle ear with internal ear
(c) Middle ear with external ear
(d) External ear with internal ear
15. Utriculus is the part of internal ear or membranous labyrinth which forms
(a) Lower chamber and is concerned with maintenance of equilibrium
(b) Lower chamber and is concerned with transmission of sound waves
(c) Upper chamber and is concerned with maintenance of equilibrium
(d) Upper chamber and is concerned with perception
16. Internal ear is filled with [AFMC 2005]
(a) Perilymph (b) Endolymph
(c) Lymph (d) Both (a) and (b)
17. Vibrations of fenestra ovalis are transmitted to
(a) Perilymph of scala vestibuli
(b) Perilymph of scala tympani
(c) Endolymph of scala media
(d) Endolymph of scala vestibuli
18. Canal joining middle ear with buccal cavity is [MP PMT 2001]
(a) Inguinal canal (b) Eustachian canal
(c) Haversian canal (d) Aquaduct of Sylvius
19. Malleus is present in the [CBSE PMT 1993]
(a) Inner ear (b) Outer ear
(c) Middle ear (d) Eye

20. Which part of the human ear plays no role in hearing as such but is otherwise very much required

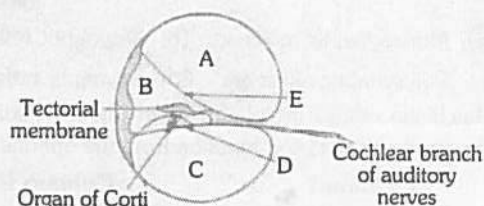
[NCERT; CBSE PMT (Pre.) 2012]

Or

Which of the following is balancing organ

[DPMT 2007; Kerala PMT 2010; AIPMT (Cancelled) 2015]

- (a) Eustachian tube (b) Organ of Corti
(c) Vestibular apparatus (d) Ear ossicles
21. The sense of equilibrium by ear is the function of
(a) Sensory cells of the organ of Corti
(b) Sensory crista of the ampulla
(c) Tectorial membrane of cochlea
(d) Basilar membrane of cochlea
22. Consider the given sectional view of Cochlea. Identify A, B, C, D and E
[NCERT; MH CET 2015]



- (a) A - Scala vestibuli, B - Scala media, C - Scala tympani, D - Reissner's membrane, E - Basilar membrane
(b) A - Scala tympani, B - Scala media, C - Scala vestibuli, D - Basilar membrane, E - Reissner's membrane
(c) A - Scala media, B - Scala vestibuli, C - Scala tympani, D - Basilar membrane, E - Reissner's membrane
(d) A - Scala vestibuli, B - Scala media, C - Scala tympani, D - Basilar membrane, E - Reissner's membrane
23. Columella auris is a modified [CBSE PMT 1992]
(a) Articular (b) Sphenoid
(c) Hyomandibular (d) Quadrate
24. A person going upto 10,000 feet high in a hot air balloon may develop severe pain in the ear due to
(a) Blocked eustachian tube
(b) Rupture of fenestra rotunda
(c) Endolymph getting into semicircular canals
(d) Fear of great height
25. Which of the following nerve supplies organ of Corti [RPMT 2002]
(a) Auditory (b) Olfactory
(c) Trochlear (d) Vagus
26. The vibrations of the tympanic membrane are amplified approximately.....times in the oval window [AMU (Med.) 2010]
(a) 5 (b) 20
(c) 40 (d) 55
27. The opening in the nasopharynx that permits air pressure on both sides of tympanic membrane of the ear to be kept equal is [AIIMS 1992; CPMT 1992; JIPMER 2002]
(a) Oval window (b) Tube of cochlea
(c) Auditory nerve (d) Eustachian tube

28. In mammalian ear, a membranous structure which separate the scala vestibuli and scala media is

[NCERT; MP PMT 2003]

- (a) Basilar membrane (b) Reissner's membrane
(c) Autolith membrane (d) Tectorial membrane

29. The organ of Corti in rabbit is concerned with the sense of [CPMT 1993; RPMT 2001; AFMC 2010]

Or

Cochlea of mammalian internal ear is concerned with

- (a) Smell (b) Hearing
(c) Taste (d) Equilibrium

30. Otoconium is found in [CBSE PMT 2000]

- (a) Perilymph (b) Haemolymph
(c) Synovial fluid (d) Otolithic membrane

31. Ear drum is known as [MP PMT 1999]

- (a) Tympanic membrane (b) Tensor tympani
(c) Scala tympani (d) Scala vestibuli

32. In the ear of man, the perilymph passes from middle to inner ear through [NCERT; CPMT 1999; JIPMER 2001]

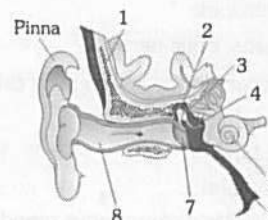
- (a) Foramen ovale (b) Fenestra ovalis
(c) Fenestra rotundus (d) Tympanic membrane

33. Organ of Corti is found in

[CPMT 1998; MHCET 2000; BVP 2001]

- (a) Internal ear (b) External ear
(c) Both (a) and (b) (d) None of these

34. See the following diagram. Identify 1 to 8 [NCERT]



- (a) 1 - Temporal bone, 2 - Malleus, 3 - Incus, 4 - Cochlea, 5 - Stapes, 6 - Eustachian tube, 7 - Tympanic membrane, 8 - External auditory canal
(b) 1 - Temporal bone, 2 - Incus, 3 - Malleus, 4 - Stapes, 5 - Cochlea, 6 - Eustachian tube, 7 - Tympanic membrane, 8 - External auditory canal
(c) 1 - Tympanic membrane, 2 - Malleus, 3 - Incus, 4 - Stapes, 5 - Cochlea, 6 - Eustachian tube, 7 - Temporal bone, 8 - External auditory canal
(d) 1 - Temporal bone, 2 - Malleus, 3 - Incus, 4 - Stapes, 5 - Cochlea, 6 - Eustachian tube, 7 - Tympanic membrane, 8 - External auditory canal

NCERT

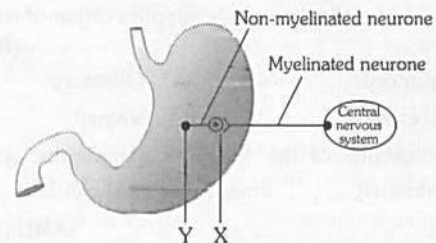
Exemplar Questions

1. Chemicals which are released at the synaptic junction are called [NCERT]

- (a) Hormones (b) Neurotransmitter
(c) Cerebrospinal fluid (d) Lymph

990 Neural Control and Coordination

2. Potential difference across resting membrane is negatively charged. This is due to differential distribution of the following ions [NCERT]
 (a) Na^+ and K^+ ions (b) CO^{3++} and Cl^- ions
 (c) Ca^{++} and Mg^{++} ions (d) Ca^{+4} and Cl^- ions
3. Resting membrane potential is maintained by [NCERT]
 (a) Hormones (b) Neurotransmitters
 (c) Ion pumps (d) None of the above
4. The function of our visceral organs is controlled by [NCERT; WB JEE 2016]
 (a) Sympathetic and somatic neural system
 (b) Sympathetic and para sympathetic neural system
 (c) Central and somatic nervous system
 (d) None of the above
5. Which of the following is not involved in Knee-jerk reflex [NCERT]
 (a) Muscle spindle (b) Motor neuron
 (c) Brain (d) Inter neurons
6. An area in the brain which is associated with strong emotions is [NCERT]
 (a) Cerebral cortex (b) Cerebellum
 (c) Limbic system (d) Medulla
7. Human eyeball consists of three layers and it encloses [NCERT]
 (a) Lens, iris, optic nerve
 (b) Lens, aqueous humor and vitreous humour
 (c) Cornea, lens, iris
 (d) Cornea, lens, optic nerve
8. Wax gland present in the ear canal is called [NCERT]
 (a) Sweat gland
 (b) Prostate gland
 (c) Cowper's gland
 (d) Sebaceous gland/ceruminous gland
9. The part of internal ear responsible for hearing is [NCERT]
 (a) Cochlea (b) Semicircular canal
 (c) Utriculus (d) Sacculus
10. The organ of corti is a structure present in [NCERT]
 (a) External ear (b) Middle ear
 (c) Semi circular canal (d) Cochlea
3. How do parasympathetic neural signals affect the working of the heart [MP PMT 1996; CBSE PMT 2014]
 (a) Both heart rate and cardiac output increase
 (b) Heart rate decreases but cardiac output increases
 (c) Reduce both heart rate and cardiac output
 (d) Heart rate is increased without affecting the cardiac output
4. The accumulation of protein called amyloid β peptide in human brain causes [Kerala PMT 2006]
 (a) Addison's disease (b) Huntington's disease
 (c) Alzheimer's disease (d) Motor-neuron disease
 (e) Parkinson's disease
5. The reflex arc which is made of two neurons is known as [WB JEE 2011]
 (a) Monosynaptic reflex arc (b) Disynaptic reflex arc
 (c) Polysynaptic reflex arc (d) Asynaptic reflex arc
6. Match the entries in column I with those in column II and choose the correct combination from the options given
- | Column I | Column II |
|-------------------|---------------|
| A. Diencephalon | 1. Cerebellum |
| B. Telencephalon | 2. Medulla |
| C. Myelencephalon | 3. Amygdala |
| D. Metencephalon | 4. Thalamus |
- [Kerala PMT 2006]
 (a) A - 4, B - 3, C - 1, D - 2
 (b) A - 3, B - 4, C - 1, D - 2
 (c) A - 4, B - 3, C - 2, D - 1
 (d) A - 1, B - 2, C - 3, D - 4
 (e) A - 4, B - 1, C - 2, D - 3
7. Suppose a person wears convex glasses for proper vision. Where you think the image of the object is formed in his eyes when he is not using the glasses
 (a) On the blind spot (b) On the yellow spot
 (c) Behind the retina (d) In front of the retina
8. The given diagram shows the parasympathetic innervation of smooth muscle and glands of the stomach



Select the right option in which the chemical transmitters are released at the synapses X and Y are correctly identified

1. Which part of the brain is involved in loss of control when a person drinks alcohol [Kerala CET 2003]
 (a) Cerebellum (b) Cerebrum
 (c) Medulla oblongata (d) Pons varoli
2. In reflex action the reflex arc is formed by [NCERT]
 (a) Brain - spinal cord - muscles
 (b) Receptor - spinal cord - muscles
 (c) Muscles - receptor - brain
 (d) Muscles - spinal cord - muscles

- (a) X - noradrenaline; Y - calcium ions
 (b) X - acetylcholine; Y - noradrenaline
 (c) X - acetylcholine; Y - calcium ions
 (d) X - acetylcholine; Y - acetylcholine

Critical Thinking

Objective Questions

9. The ventricles of the brain are filled with [DPMT 1993]
 (a) Cerebro-spinal fluid (b) Lymph
 (c) Blood (d) Amniotic fluid

10. In Myasthenia gravis acetylcholine [AMU (Med.) 2010]
 (a) Receptors on motor end plate are reduced
 (b) Secretion from nerve terminals is reduced
 (c) Esterase activity is inhibited
 (d) Secretion from nerve terminals is enhanced

11. Vagus (Pneumogastric) nerve is [CBSE PMT 1992; BVP 1997, 2001; KCET 1998; Wardha 2005; WB JEE 2016]
 (a) Spinal nerve (b) Sympathetic nerve
 (c) X-cranial nerve (d) Parasympathetic nerve

12. Which one is the function of parasympathetic nervous system in mammals [CBSE PMT 1990]
 (a) Acceleration of heart beat
 (b) Constriction of pupil
 (c) Stimulation of sweat glands
 (d) Contraction of arrector pilli muscles

13. Which cranial nerve carries in excitation from the ear [MP PMT 1994]

Or

The cranial nerve which brings impulses from the internal ear is [MP PMT 2013]

- (a) Optic (b) Auditory
 (c) Olfactory (d) Trigeminal

14. Which is a characteristic of a graded potential [AMU (Med.) 2009]

- (a) The amplitude is always the same
 (b) The duration varies
 (c) Always followed by a refractory period
 (d) Is an all or none response

15. The centre for sense of smell in brain is [MP PMT 1999, 2003; AFMC 2003, 05; MH CET 2004, 07]

- (a) Cerebellum (b) Cerebrum
 (c) Olfactory lobes (d) Midbrain

16. Brain depends on blood for the supply of [CPMT 1999; RPMT 1999; JIPMER 2001]

- (a) Oxygen and ATP (b) Oxygen and electrolytes
 (c) Oxygen and glucose (d) ATP and glucose

17. The sound waves produce the vibrations in the endolymph, which in turn affects one of the following to produce the stimuli for hearing

- (a) Basilar membrane (b) Tectorial membrane
 (c) Reissner's membrane (d) Cochlear duct

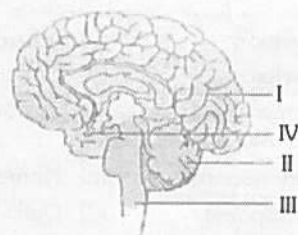
18. The venom of cobra affects the [JIPMER 1994; BVP 2000; AFMC 2009; MP PMT 2013]

- (a) Digestive system (b) Circulatory system
 (c) Nervous system (d) Respiratory system

19. The jumping of action potential from node to node (of Ranvier) in a fibre is called [CPMT 1992]

- (a) All or none principle (b) Threshold stimulus
 (c) Nodal conduction (d) Saltatory conduction

20. The given diagram is that of human brain



Which functions is performed by the part labelled III in the given diagram [NCERT]

- (a) Maintaining posture
 (b) Controlling learning
 (c) Regulation of heartbeat
 (d) Regulation of body temperature

21. Molecules that bear charged groups of opposite polarity are known as [DUMET 2010]

- (a) Zwitterions (b) Cations
 (c) Anions (d) Negative ions

22. Synaptic fatigue is due to

- (a) Exhaustion of neurotransmitter
 (b) Release of more acetylcholine
 (c) Release of more adrenaline
 (d) None of these

23. A touch on the right hand stimulates neurons in [Odisha JEE 2005]

- (a) Left somatic sensory area
 (b) Right somatic sensory area
 (c) Both (a) and (b)
 (d) None of these

24. Read the following statements and choose the correct option

- A. Blood cells secrete fibres of structural proteins called collagen or elastin
 B. Neuroglial cells protect and support the nephrons
 C. Osteocytes are present in spaces called lacunae
 D. Striated muscle fibres are bundled together in a parallel fashion
 E. Biceps are involuntary and striated

[Kerala PMT 2012]

- (a) C and D alone are wrong
 (b) B and D alone are wrong
 (c) A and C alone are wrong
 (d) B and C alone are wrong
 (e) A, B, and E alone are wrong

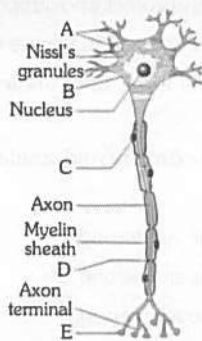
25. Small lesions on spinal tissue, slip disc in spinal column and micro cancer like tumour are detected by

[AMU (Med.) 2005; Kerala PMT 2009]

- (a) Magnetic resonance imaging method
 (b) Sonography method
 (c) Positron Emission Tomography method
 (d) X-ray Radiography method

992 Neural Control and Coordination

26. Manifestation of increase in the blood pressure of a person is called [J & K CET 2005]
 (a) Hypertension (b) Atherosclerosis
 (c) Arteriosclerosis (d) None of these
27. Mouth becomes watery when we look on the delicious food is due to [J & K CET 2005]
 (a) Olfactory response (b) Hormonal response
 (c) Neural response (d) Optic response
28. An action potential in the nerve fibre is produced when positive and negative charges on the outside and the inside of the axon membrane are reversed, because [AIIMS 2007]
 (a) More potassium ions enter the axon as compared to sodium ions leaving it
 (b) More sodium ions enter the axon as compared to potassium ions leaving it
 (c) All potassium ions leave the axon
 (d) All sodium ions enter the axon
29. Taste buds detect the substance only when the substance is
 (a) Solid (b) Semisolid
 (c) Semiliquid (d) Liquid
30. 'Adaptation' of eyes in dark is due to [BHU 2005]
 (a) Depletion of vision pigment in rod
 (b) Depletion of vision pigment in cones
 (c) Repletion of vision pigment in rods
 (d) Repletion of vision pigment in cones
31. In mammals, sound wave receptors are [MP PMT 1998]
 (a) Ears (b) Eyes
 (c) Skin (d) Hair
32. Organs of Ruffini are receptors of [BHU 1995; AMU (Med.) 2006; MP PMT 2007]
 (a) Heat (b) Cold
 (c) Pressure (d) Touch
33. The given figure show the structure of neuron. Identify A, B, C, D and E [NCERT]



	A	B	C	D	E
(a)	Dendrites	Cyton or cell body	Nerve cell	Node of Ranvier	Synaptic knob
(b)	Dendrites	Nerve cell	Schwann cell	Node of Ranvier	Synaptic knob
(c)	Dendrites	Cyton or cell body	Schwann cell	Node of Ranvier	Synaptic knob
(d)	Nerve fibre	Cyton or cell body	Schwann cell	Node of Ranvier	Synaptic knob

34. When the intensity of light is low during night, the light is detected by [MP PMT 1996, 2002, 11]
 (a) Rods (b) Cones
 (c) Lens (d) Both rods and cones
35. Fovea centralis of retina perceives [MP PMT 1992]
 (a) Diffused light (b) Dim light
 (c) Coloured light (d) Coloured and dim light
36. Eye is said to be near-sighted when a [MP PMT 1992]
 (a) Near object is focussed in front of the retina
 (b) Distant object is focussed in front of retina
 (c) Near object is focussed behind the retina
 (d) Distant object is focussed behind the retina
37. If an organism has more rods it will [BVP 2004]
 (a) Active during day
 (b) Possess colour vision
 (c) Active during night
 (d) Both 'a' and 'c' are possible
38. The pupil becomes bigger to allow more light during dark by the
 (a) Contraction of radial muscles of the iris
 (b) Relaxation of radial muscles of the iris
 (c) Contraction of circular muscles of the iris
 (d) Contraction of suspensory ligaments
39. The part of an eye which acts like a diaphragm of a photographic camera is
 (a) Pupil (b) Iris
 (c) Lens (d) Cornea
40. The defective condition of accommodation of the eye in which distant objects are seen distinctly but near objects are indistinct is [AFMC 1994]
 (a) Astigmatism (b) Presbyopia
 (c) Myopia (d) Hypermetropia
41. The point in eye of mammals from which optic nerves and blood vessels leaves the eye ball is [NCERT; AFMC 2004]
 (a) Yellow spot (b) Blind spot
 (c) Pars optica (d) None of these
42. Fishes have very poor sense organs for [BHU 2000]
 (a) Detecting odours
 (b) Light perception
 (c) Sound perception
 (d) Detecting vibrations in water
43. The eyes of cat, cow, buffalo and some nocturnal animals shine in night. It is due to the presence of tapetum lucidum between the choroid and retina. This shining is due to the presence of a pigment made of
 (a) Cytocine (b) Uracil
 (c) Guanine (d) Thiamine
44. In which direction cristae of rabbit ear helps in maintaining balance [RPMT 2006]
 (a) Circular position of longitudinal axis of semi circular canals
 (b) Transverse position of longitudinal axis of semi circular canals
 (c) Parallel to longitudinal axis of semi circular canals
 (d) All of the above

45. In cataract [RPMT 2001; JIPMER 2002]
 (a) Due to ageing or some infection eye lens becomes opaque
 (b) Elasticity of eye lens is lost
 (c) There is irregular curvature of lens
 (d) Eye ball becomes shorter
46. How many eye muscles are present which control all types of eye movement
 (a) 3 (b) 4
 (c) 5 (d) 6
47. Bowman's glands are located in the [MP PMT 1998; CBSE PMT 2007]
 (a) Proximal end of uriniferous tubules
 (b) Anterior pituitary
 (c) Female reproductive system of cockroach
 (d) Olfactory epithelium of our nose
48. What is the correct sequence of the parts of the eye that the light rays cross in reaching the retina [CMC Vellore 1993]
 (a) Pupil → cornea → aqueous humour → lens → vitreous humour
 (b) Lens → cornea → aqueous humour → vitreous humour → pupil
 (c) Aqueous humour → vitreous humour → cornea → pupil → lens
 (d) Cornea → aqueous humour → pupil → lens → vitreous humour
49. The cornea is a very important component of the human eye. The main function of the cornea is to [AIIMS 2010]
 (a) Bend the light before it reaches the lens
 (b) Provide structural support to the eye
 (c) Contain a concentrated amount of cone cells in the correct orientation
 (d) Change the shape of the lens to enable the image to be focused on the retina

Assertion & Reason

Read the assertion and reason carefully to mark the correct option out of the options given below :

- (a) If both the assertion and the reason are true and the reason is a correct explanation of the assertion
 (b) If both the assertion and reason are true but the reason is not a correct explanation of the assertion
 (c) If the assertion is true but the reason is false
 (d) If both the assertion and reason are false
 (e) If the assertion is false but reason is true

1. Assertion : The imbalance in concentration of Na^+ , K^+ and proteins generates resting potential.
 Reason : To maintain the unequal distribution of Na^+ & K^+ , the neurons use electrical energy. [AIIMS 2002, 09]

2. Assertion : Rabies is acute infectious disease of warm blooded mammals characterized by involvement of central nervous system resulting in paralysis and finally death.
 Reason : This is caused due to neurotropic filterable bacteria in saliva of rabid animals. [AIIMS 2000]
3. Assertion : Transmission of the nerve impulse across a synapse is accomplished by neurotransmitters.
 Reason : Transmission across a synapse usually requires neurotransmitters because there is small space i.e. synaptic cleft, that separates one neuron from another. [AIIMS 1999]
4. Assertion : Medulla oblongata causes reflex actions like vomiting, coughing and sneezing.
 Reason : It has many nerve cells which control autonomic reflexes. [AIIMS 1994]
5. Assertion : Anterior lobe of pituitary is attached to hypothalamus by a vein.
 Reason : This attachment is done through a portal vein. [AIIMS 1993]
6. Assertion : After hearing a sound, nerve impulse passes from neurons to the brain.
 Reason : The neurons which pass nerve impulses from the body organ to the brain is called afferent neuron.
7. Assertion : Cerebrospinal fluid is present throughout the central nervous system.
 Reason : CSF has no such function.
8. Assertion : All motor neurons are efferent neurons.
 Reason : Motor neurons conduct nerve impulses from the spinal cord to the brain.
9. Assertion : Some areas of the brain and spinal cord look white.
 Reason : This is because cell bodies of neurons are situated in those areas.
10. Assertion : In man, only peripheral nervous system is present.
 Reason : The peripheral nervous system includes nerves coursing between the central nervous system and different parts of the body.
11. Assertion : Spinal cord has a column of both grey and white matter.
 Reason : Grey matter forms the central spinal canal.
12. Assertion : Vitamin A deficiency produces night blindness.
 Reason : Photosensitive pigment rhodopsin is synthesised from vitamin A.
13. Assertion : Tongue is a gustatoreceptor.
 Reason : Receptors for gustatory sensations are located in the taste bud. [AIIMS 2000]

994 Neural Control and Coordination

14. Assertion : Circular smooth muscles of iris contract when bright light falls on the eye.
Reason : Pupil gets constricted by the contraction of circular smooth muscles of iris.
15. Assertion : Sparrows possess poor night vision.
Reason : Sparrows eyes are made up of ommatidia.
16. Assertion : The eye is said to have power of accomodation.
Reason : Ciliary muscles alters the shape of the lens for near or far vision during accomodation.
17. Assertion : Nerve fibre can become excited through touch, smell, pressure and chemical changes and there is a change in polarity.
Reason : It is called active potential [GUJCET 2015]

Answers

Development of central nervous system in human

1	b	2	c	3	a	4	a	5	b
6	d	7	a	8	d	9	b		

Part of nervous system

1	c	2	c	3	d	4	d	5	a
6	d	7	b	8	b	9	a	10	a
11	a	12	a	13	a	14	c	15	d
16	a	17	d	18	e	19	a	20	a
21	d	22	b	23	d	24	b	25	d
26	a	27	a	28	b	29	b	30	a
31	a	32	a	33	d	34	d	35	b
36	c	37	c	38	e	39	a	40	a
41	c	42	b	43	c	44	d	45	a
46	b	47	c	48	a	49	c	50	a
51	a	52	a	53	b	54	d	55	d
56	a	57	d	58	b	59	a	60	d
61	b	62	a	63	d	64	a	65	c
66	d	67	a	68	c	69	b	70	a
71	c	72	a	73	b	74	c	75	a
76	a	77	c	78	c	79	d	80	d
81	c	82	c	83	a	84	a	85	a
86	b	87	c	88	a	89	d	90	a
91	c	92	b	93	d	94	c	95	c
96	b	97	c	98	c	99	b	100	d
101	a	102	c	103	c	104	b	105	d
106	d	107	c	108	b	109	d	110	b
111	b	112	a	113	c	114	a	115	a
116	a	117	b	118	c	119	b	120	a
121	b	122	c	123	b	124	a	125	a
126	c	127	ad						

Biochemical aspect of nervous physiology

1	c	2	b	3	d	4	c	5	d
6	a	7	b	8	a	9	b	10	a
11	b	12	b	13	a	14	a	15	b
16	a	17	d	18	a	19	a	20	b
21	c	22	a	23	d	24	b	25	c
26	a	27	d	28	c	29	b	30	d
31	a	32	a	33	c	34	a	35	b
36	a	37	d	38	c	39	d	40	b
41	d	42	b	43	d	44	d	45	b
46	b	47	c	48	d	49	d	50	b
51	d	52	d	53	a	54	a	55	c
56	a	57	e	58	d	59	d	60	d
61	c	62	c	63	abd	64	d	65	a

Different types of Receptors

1	b	2	b	3	c	4	a	5	c
6	c	7	b	8	d	9	c	10	a
11	a	12	d	13	c	14	d	15	b

Eye

1	c	2	b	3	c	4	d	5	d
6	d	7	a	8	b	9	a	10	b
11	a	12	c	13	a	14	b	15	c
16	c	17	a	18	a	19	d	20	b
21	d	22	d	23	a	24	d	25	a
26	e	27	b	28	a	29	d	30	e
31	a	32	a	33	d	34	a	35	c
36	c	37	d	38	b	39	b	40	a
41	b	42	c	43	a	44	b	45	b
46	d	47	c	48	b	49	b	50	d
51	a	52	d	53	c	54	d	55	d
56	b	57	d	58	b				

Ear

1	c	2	c	3	e	4	b	5	c
6	c	7	a	8	a	9	d	10	c
11	b	12	d	13	a	14	a	15	c
16	d	17	a	18	b	19	c	20	c
21	b	22	d	23	c	24	b	25	a
26	b	27	d	28	b	29	b	30	d
31	a	32	b	33	a	34	d		

NCERT Exemplar Questions

1	b	2	a	3	c	4	b	5	c
6	c	7	b	8	d	9	a	10	c

Critical Thinking Questions

1	a	2	b	3	c	4	c	5	a
6	c	7	c	8	d	9	a	10	a
11	cd	12	b	13	b	14	c	15	c
16	c	17	b	18	c	19	d	20	c
21	a	22	a	23	a	24	e	25	a
26	a	27	c	28	b	29	d	30	c
31	a	32	a	33	c	34	a	35	c
36	b	37	c	38	a	39	b	40	d
41	b	42	c	43	c	44	b	45	a
46	d	47	d	48	d	49	a		

Assertion and Reason

1	c	2	c	3	a	4	a	5	b
6	b	7	c	8	c	9	c	10	e
11	b	12	a	13	a	14	b	15	c
16	b	17	b						

AS Answers and Solutions

Development of central nervous system in human

- 2. (c) Corpus callosum is a thick whitish band of semicircular nerve fibres interconnecting two cerebral hemispheres (found only in mammals).
- 4. (a) Largest cell in the body is neuron. Certain neurons may almost equal the length of body itself.
- 5. (b) Optic nerve is sensory, therefore it originates from retina and is distributed in mid-brain.
- 7. (a) Sympathetic nervous system increases defence system of body against adverse conditions. It is active in stress condition. Such as pain fear and anger.
- 8. (d) Autonomic nervous system regulates and coordinates involuntary activities like heart beating, homeostasis, body temperature, breathing, gut peristalsis and secretion of glands.

Parts of nervous system

- 1. (c) VIII, the auditory cranial nerve.
- 3. (d) A mammal, from whose brain cerebrum is removed loses all responses that depend upon consciousness and memory.

- 4. (d) Hind brain has two distinct part (i) metencephalon (medulla oblongata) (ii) myelencephalon (cerebellum), transverse band of white matter called pons varoli.
- 5. (a) Cerebellum is responsible for co-ordination of body movements.
- 6. (d) Reflex action is an immediate involuntary response to a stimulus with out the intervention of brain, controlled by spinal cord of central nervous system.
- 7. (b) Man has 31 pairs of spinal nerves while rabbit has 37 pairs.
- 8. (b) III, IV and VI cranial nerves.
- 9. (a) The smallest cranial nerve is trochlear in human beings.
- 10. (a) The post-ganglionic nerve fibres of sympathetic nervous system are adrenergic *i.e.*, they release the neurotransmitter nor-adrenaline at their termination. The sympathetic nerves stimulate the adrenal glands to secrete adrenaline.

The post-ganglionic para-sympathatic fibres are cholinergic *i.e.*, they release a chemical substance acetyl choline, a neurotransmitter, at their endings for the transmission of nerve impulses.

- 11. (a) Ependymal cells are columnar cells that have ciliated surface. They support the central nervous system and also nutritive in function.
- 12. (a) Sympathatic nerves are composed of efferent fibres derived from the thoracic and lumbar regions of the spinal cord.
- 15. (d) Accessory nerves arise from the side of medulla oblongata and supply to the muscles of the pharynx, larynx neck and shoulder. They are motor nerves.
- 16. (a) Between paracoel and diocoel.
- 20. (a) Arbor vitae is a branched tree like structure composed of white matter in cerebellum.. It is also presumed to be the seat of soul.
- 22. (b) Abducens is motor nerve which arise from the ventral surface of medulla oblongata these nerve helps in rotation of eye balls. The optic are sensory nerve. Ophthalmic and palatinus are mixed nerve.
- 31. (a) Parasympathetic nervous system stimulates the peristaltic movement of digestive tract, contracts the wall of urinary bladder and reduces the diameter of the pupil by contracting the iris.
- 32. (a) It coordinates the activity of both the cerebral hemispheres.
- 33. (d) Hypothalamus contains higher nerve centres for temperature regulation, hunger, thirst and emotional reactions.
- 37. (c) Hypothalamus is the floor of diencephalon which is the part of fore brain. It has thermoregulatory centre, hunger and thirst centre.
- 38. (e) Crura cerebrae are thickened ventral portions of the mid-brain of a vertebrate consisting of nervous tracts linking the thalamencephalon with the hind-brain.

996 Neural Control and Coordination

39. (a) Reflexes are classified as the spinal reflexes and the cranial reflexes. The former are so called because their basic neural path leads through spinal nerves and spinal cord. Reflexes at the spinal level have the purpose of removing the animal from harmful stimuli.
40. (a) Parkinson's disease or paralysis agitans is a defect of brain.
41. (c) The primary acoustic centre is in the temporal lobe of cerebral hemispheres.
42. (b) Occipital lobe is the centre for sight as the greater part of the visual area lies in it.
43. (c) All spinal nerves are sensory and motor both (mixed).
44. (d) Central nervous system comprises brain and spinal cord both are surrounded by the three protective membranes these are duramater, arachnoid mater – piamater.
45. (a) Cerebellum primary functions is to maintain posture, orientation and equilibrium of body by co-ordinating and regulating tone and contraction of voluntary muscles, mainly according to the commands of cerebellum.
48. (a) The motor cranial nerves are III, IV, VI, XI and XII.
49. (c) The thick wall of spinal cord consists of an inner zone of grey matter and a peripheral zone of white matter.
52. (a) Oculomotor nerve has oculomotor nucleus and Edinger–Westphal nucleus.
55. (d) The upper or superior surface of the "mid brain" has two pairs of rounded protrusions collectively called the corpora quadrigemina one pair is called superior colliculi and the other pair is called inferior colliculi. In frog, corpora quadrigemina are the optic lobes. The superior colliculi are concerned with sense of sight. However inferior colliculi are concerned with hearing.
56. (a) Reflexes developed by training and learning are called conditioned or acquired reflexes for example after proper learning, we can perform dancing, cycling, swimming, singing, playing etc. simply by reflexes.
57. (d) Autonomic nervous system controls involuntary functions of the visceral organs.
59. (a) Conditional reflexes were first demonstrated by the Russian scientist, Pavlov in dogs.
61. (b) Nerve that connect only receptor organs to the CNS are purely sensory or afferent nerve because these contain only sensory nerve fibres.
62. (a) Reflex is the spontaneous automatic mechanical response to a stimulus without animals' s will.
63. (d) Ventricles I and II of cerebral hemispheres are called as paracoels or lateral ventricles. Ventricle III is known as diocoel. Ventricle IV is the metacoel.
65. (c) Vagus nerve has five branches –
(i) Superior laryngeal nerve
(ii) Recurrent laryngeal nerve
(iii) Cardiac nerve
(iv) Pneumogastric nerve
(v) Depresser nerve
66. (d) Broca's area is the speech centre which controls the movement of lips, tongue, larynx, pharynx etc.
67. (a) Brain and spinal cord are surrounded by three meninges – duramater and piamater, arachnoid in mammals.
68. (c) It is found at the roof of diencephalon. The anterior part of the diencephalon is vascular and folded to form the anterior choroid plexus.
69. (b) Nerve cell are highly specialized cell which have no power of division because they do not have centrosome.
70. (a) This is also sensory. It brings sensory impulse from the skin of upper lip upper jaw, nasal mucosa and lower eyelids.
72. (a) The medulla oblongata passes out through the foramen magnum and continues into spinal cord, which is contained in the neural canal of vertebral column.
75. (a) The cavity of the hind brain, called fourth ventricle, is rhomboidal and limited to the anterior part of medulla oblongata.
77. (c) The cavities (= lateral ventricles or paracoels) of the cerebral hemispheres remain separate in frontal lobes. In temporal lobes these join together and communicate behind, by a common foramen of monro, with the diocoel (3rd ventricle) cavity of diencephalon.
78. (c) Wernicke's area is responsible for understanding speech.
79. (d) Neurons the specialized all of nervous system. In nervous system has no power of regeneration.
80. (d) Reflex arc is the basic functional unit of nervous system. The entire impulse circuit of a reflex response.
receptors → CNS → effector
81. (c) Cervical – 8 pairs, thoracic – 12 pairs, lumbar – 7 pairs, sacral – 4 pairs, caudal – 6 pairs *i.e.* total 37 pairs.
82. (c) Trigeminal nerve is the fifth cranial nerve of frog. It arises from the antero-lateral sides of medulla oblongata.
83. (a) A band of white nerve fibres, the corpus callosum connects the two cerebral hemispheres together in mammalian brain.
85. (a) In which sympathetic nerve fibres are included.
88. (a) Abducens is the sixth number of motor cranial nerve which regulate the movement of eye ball.

89. (d) In human beings, the 12 pairs of cranial nerves and 31 pairs of spinal nerves and 12 pairs of Ribs are present.
94. (c) I, II and VIII i.e. olfactory, optic and auditory.
95. (c) Ventricle III is known as diocoel is a small cavity of diencephalon.
97. (c) X-cranial nerve controls the visceral sensation, and visceral movements (peristalsis, sound production, respiratory movements, heart beat)
99. (b) Ivan Pavlov of Russia (1906), on the basis of experiments with dogs showed that conditioned reflex affects behaviour.
101. (a) The nerve fibres of ventral root carry motor impulses away from the spinal cord.
102. (c) Sensory nerve fibres are located in the dorsal root ganglion.
104. (b) The medullary sheath, or myelin sheath is continuous around the nerve fibres in the CNS but in the nerve fibres of PNS it is absent.
105. (d) Autonomic response obviously occur very fast we do not even feel the stimulus. Thus reflex reaction protect the body against injurious effects of sudden stimuli.
106. (d) Cerebrum (cerebral hemisphere) is centre of thinking, will power, reasoning and memory, experience and learning knowledge and articulate speech.
108. (b) Lateral ventricles are cavities of cerebrum.
109. (d) Medulla oblongata contains centre for the autonomic reflex control of respiration, heart beat and these centre are called vital centres because damage to them is usually total.
112. (a) Myelinated or medullated nerve fibre (Axon) is surrounded by inner thick medullary sheath of fatty matter called myelin.
114. (a) The thin roof of III ventricle (diocoel) is called epithalamus. The anterior part of epithalamus contains a highly coiled bunch of blood capillaries called anterior Choroid plexus. The dorsal surface of metacoel also contains highly coiled bunch of blood capillaries called post choroid plexus.
115. (a) Axon is a single long process of uniform thickness. It contain neurofibrils and neurotubules but lack nissle's granules, golgi complex ribosomes etc.
116. (a) Broca's area is part of frontal lobe of cerebrum is related with speech.
117. (b) Sympathetic nervous system increases the (i) rate and force of heart beat, (ii) constricts most blood vessels, (iii) raises the arterial blood pressure, (iv) dilates the pupil, (v) slows down peristaltic movements, (vi) and relax the urinary bladder.
118. (c) 3rd, 6th, 11th cranial nerve are oculomotor, abducens and spinal accessory respectively. All of these are motor nerve.
119. (b) Foramen of monro is the space in the brain of frog and rabbit which joins lateral ventricle of diocoel to the III ventricle of brain.
120. (a) Subarachnoid space is found between arachnoidmater and piamater. It contains CSF. It is absent in frog but present in mammals.
122. (c) In myogenic heart, heart beat is continuous even after the nerve supply is cut.
123. (b) The cranial nerve III, IV and VI are motor nerve and control eye ball movement known as III oculomotor IV trochlear and VI Abducens nerve.
124. (a) Unconditioned reflexes are inborn, inherited and species specific and stable and controlled by spinal cord.
Conditioned reflexes are acquired by learning and experiences and controlled by cerebral cortex of brain.
125. (a) Nodes of Ranvier are uncovered part of an axon.
126. (c) Cerebrum is the part of fore-brain, which develops from embryonic prosencephalon.
127. (ad) Parasympathetic nervous system includes four cranial nerves - III [Oculomotor] VII [Facial], IX [Glossopharyngeal] and X [Vagus].

Biochemical aspect of nervous physiology

4. (c) Nerve impulses are transmitted from axon to dendron with the help of acetylcholine and adrenaline called neurotransmitters, produced by the secretory vesicles of the synaptic knob.
6. (a) The movement of Na⁺ into the axoplasm leads to the depolarization of nerve.
13. (a) Arrival of an impulse at the synaptic knob causes the acetylcholine to be discharged into synaptic cleft.
20. (b) (a) During resting membrane potential, Na⁺ ions are more on the outer side of membrane due to Na⁺ - K⁺ ion pumps; (b) Action potential lasts only for very short time and Na⁺ ions are more on the inner side of membrane; (c) During depolarization, Na⁺ ion channels open leading to influx of Na⁺ developing positive charge on inner side of plasma membrane; (d) During repolarization, Na⁺ ion channel get closed and K⁺ ion channels open leading to efflux of K⁺ moving it outside of membrane.
23. (d) Efflux of K⁺ causes repolarization. Therefore it is the movement of K⁺ that maintains the depolarized state.

998 Neural Control and Coordination

26. (a) In poliomyelitis, anterior horn cells of spinal cord are destroyed which result in loss of motor activities of limbs.
28. (c) At the end of repolarization, a difference in concentration of positive ions on two sides of plasma membrane is generated leading to ionic imbalance. During repolarization, K^+ ion channels open up and K^+ ions move out of the plasma membrane.
29. (b) Nerve impulse carry through afferent nerve fibres from receptors to central nervous system.
30. (d) It is a strong insulating layer which prevents almost all flow of ions through the axonic surface and thus prevent the leakage of impulse.
34. (a) On medullated nerve fibres speed of nerve impulse is about 20 times faster than on non-medullated nerve fibres.
36. (a) In a synapse, the transmitting cell is called the presynaptic cell and the gap in between is called a synaptic cleft. Synaptic vesicles are found in presynaptic neuron. They contain neurotransmitters which on stimulation are released into the synaptic cleft and then these chemicals combine with the receptors on the postsynaptic neuron causing depolarization.
37. (d) Na^+ enters in the axoplasm leading to depolarization of the nerve.
39. (d) Nerve impulse is a self propagating wave of depolarization and repolarization.
42. (b) Sub-arachnoid space found between the arachnoid membrane and pia-mater, which is filled with cerebro-spinal fluid.
43. (d) Animals have two system of co-ordination i.e., nervous system and endocrine system. Neurones are the basic structural and functional units of the nervous system which spread through out the organism forming a complex communication network. Endocrine system release hormone for intercellular communication.
44. (d) Gamma amino butyric acid (GABA) and glycine are inhibitory transmitters. An inhibitory transmitter is one that is released by an inhibitory neuron. It can inhibit impulse at synapse.
45. (b) Transmission of nerve impulse, across a synapse is accomplished by neurotransmitters because of synapse. It separates one neuron from other.
47. (c) Parkinson's disease is characterised by tremors and progressive rigidity of limbs caused by a degeneration of brain neurons and a neurotransmitter called dopamine.
48. (d) Autonomic nervous system regulates and coordinates involuntary activities like heart beating, homeostasis, body temperature, breathing, gut peristalsis and secretion of glands.
49. (d) The post ganglionic parasympathetic fibres release a chemical substance acetylcholine.
51. (d) Hypothalamus contains higher nerve centre for temperature regulation, hunger, thirst and osmoregulation.
56. (a) When a neuron is in resting state i.e., not conducting any impulse, the axonal membrane is comparatively more permeable to K^+ ions and nearly impermeable to Na^+ ions.
62. (c) Neuromuscular junction is the junction between motor neuron and muscle fibre.
63. (abd) Tyrosine amino acid is required for synthesis of dopamine. Adrenaline is formed by methylation of nor-adrenaline using Phenylethanolamine N-methyltransferase.
65. (a) In CNS, myelin sheath is formed by oligodendrocytes, while in PNS, it is formed by Schwann cells

Different types of Receptors

- (b) Pacinian corpuscles are tactile receptors occur in deeper layer of skin in neck, arms, nipples, external genital, palms and soles. These receive stimulus of strong pressure and vibrations of sustained contacts.
- (b) Rod is a kind of light-sensitive nerve cell present in vertebrate retina. Rods do not discriminate fine details or colour differences.
- (c) Neuromast organs are little groups of receptor and supporting ectodermal cells found in the lateral line canals. Neuromast organs are current receptor or rheoreceptor and can perceive vibration of very low frequency.
- (a) Jacobson's organ (vomeronasal organ) is concerned with smell.
- (c) Jacobson's organs are present in the anterior part of nasal cavity which is well developed in snakes and lizards while vestigial organ in man.
- (b) A small, bipectinate chemoreceptor called osphradium is present in the mantle cavity of Pila and is sensible to chemical stimulus.
- (d) Meissner corpuscles are specialised sense organs situated immediately beneath epidermis in the skin. These respond to touch and pressure.
- (c) Long stiff tactile hairs, the vibrissae (pili tactiles) project from the side of mouth, external nares and above the eye.
- (d) Proprioceptors are situated internally, and detect changes in the internal environment of body.
- (d) Bats produce subsonic sound which are received by ear after being reflected by the surrounding objects. The time taken by the echo indicates the distance of object to bat.
- (b) Proprioceptor are sensory nerve ending located deep with muscles, tendons, joints and vestibular apparatus that respond to stimuli originating from within the body regarding movement and spatial position.

Eye

1. (c) Iris is a pigmented disc like part which is found between cornea and lens. Iris consist of circular sphincter and radial dilators muscles which controls the light entering into the eye.
2. (b) Choroid is the middle pigmented and vascular layer in the wall of the eye of a vertebrate between retina and sclerotic coat.
3. (c) Rhodopsin is a visual purple pigment (formed by vitamin A and opsin protein) sensitive to dimlight. It helps in twilight vision during night.
4. (d) Fovea is present at centre of macula lutea, which is centre of highest resolution, has only cones
6. (d) In glaucoma, there is over production of vitreous humour which increases the pressure in the eye and this crushes the delicate cells of the retina, causing blindness.
9. (a) Blind spot in the eye is the place where neither rods nor cones present.
13. (a) Vitamin A is the precursor of the purplish red pigment rhodopsin contained in the rods (photoreceptor) cells of human eye.
14. (b) Iodopsin is photosensitive visual pigment found in cones of retina.
20. (b) The muscles associated with the iris regulate the amount of light entering the eyeball by varying the size of the pupil.
28. (a) The eye lens is made of transparent proteins called crystallins. The proteins are arranged in approximately 20,000 thin concentric layers. The average concentration of lens protein is about twice than that of other intracellular proteins & is thought to play a structural role in the lens.
31. (a) Unstriped or non striated or visceral or smooth or involuntary muscles are found in iris of eye, oesophagus, stomach, intestine lungs, urinogenital tract, urinary bladder and blood vessels.
35. (c) Each eye of cockroach is a compound structure of about 2000 ommatidia which are the visual units of photoreception.
36. (c) Myopia is near sightedness. In this defect, the light rays converge in front of retina causing a blurred image.
37. (d) Owl is able to see at night but has poor day vision due to the presence of only rods in eyes.
40. (a) Glucoma develops due to increased intraocular tension as a result of blocking of canal of schlemm. The pressure in eye rises above the normal range of 15-20 mm of Hg since to aqueous humour is not drained out into the blood.
43. (a) Central opening of iris is called pupil which controls the light entering into eye.
46. (d) The posterior part of the retina, which is just opposite to the lens is called area centralis or yellow spot, which contains only cones and has yellow pigment, the images are normally focussed on this area.
47. (c) Fovea centralis, a shallow depression at the middle of yellow spot (macula lutea), has only cone cells and is the place of most distinct vision.
52. (d) Choroid in the middle layer of the eye which is highly vascular and covered with pigment cells.
53. (c) The cones are about 300 times less sensitive than the rods but even this allows colour vision in any light greater than dimlight.
58. (b) Cone cells of retina are related to Photopic vision and also for perception of colours.

Ear

1. (c) Pinna collects the sound vibrations and reflect them into external auditory canal. Besides this it also helps in localisation of sound source.
2. (c) The *scala vestibuli* and *scala tympani* are filled up with perilymph and communicates with each other at the apex through a small opening *helicotrema* i.e., *scala vestibuli* is connected with *scala tympani*.
5. (c) Acoustic spots occur in the ampullae of semicircular ducts of internal ear or the membranous labyrinth. The wall of the membranous labyrinth of frog is lined with cubical epithelial cells. The epithelial lining, at certain places, is modified to form sensory patches called acoustic spots. There exists one in the utriculus, one in the sacculus, and one in the lagens. The sensory paths of ampullae are called cristae, while the other one are known as maculae.
7. (a) These are called the *limits of audibility*. Actual value is 20 to 20000 cycles/sec.
10. (c) Perilymph is clear fluid present in the bony labyrinth of ear.
19. (c) Three auditory ossicles in the middle ear are malleus incus and stapes.
20. (c) The crista and macula are the specific receptors of the vestibular apparatus responsible for maintenance of balance of the body and posture. These play no role in hearing.
23. (c) Hyomandibular is one pair of small cartilages or bone forming the dorsal ends of the hyoid arch of a vertebrate. Hyomendibular becomes modified to form an auditory ossicle the columella auris of amphibia, reptiles and birds and the stapes of mammals.
25. (a) Cochlear branch of auditory nerve supplies the organ of corti.
27. (d) The function of eustachian tube is to equalize air pressure on both side (external and middle ear) of tympanic membrane.

1000 Neural Control and Coordination

28. (b) The scala vestibuli and scala media are separated by Reissner's membrane which makes up the roof or dorsal wall of the scala media.
29. (b) Organ of Corti is the auditory sense organ within the spiral cochlea of mammalian ear.
30. (d) The otolithic membrane contains numerous minute, irregular particles called otoliths or otoconia which are made up of calcium carbonate and protein.
31. (a) Ear drum is also known as tympanic membrane which separates middle ear from external ear.
34. (a) Rods are sensitive to dimlight.
36. (b) Myopia or near sightedness is related abnormalities of eye in which eye ball becomes elongated, increasing the horizontal axis of eye. The image is formed before retina instead of upon it.
39. (b) The iris of eye can be compared with the diaphragm of a camera as it regulates the amounts of light entering in eye by constricting or dilating the pupil.
43. (c) Many nocturnal mammals also have tapetum lucidum which contain light reflecting crystals of guanine.
44. (b) The cristae of rabbit ear helps in maintaining balance in transverse position of longitudinal axis of semicircular canals.

Critical Thinking Questions

1. (a) Because cerebellum is not concerned with conscious sensations. It maintains equilibrium.
2. (b) Reflex arc is the pathway taken by nerve impulse generated at the receptors due to stimulus to reach the effector organ during reflex action.
3. (c) Post-ganglionic fibers of parasympathetic nervous system secrete acetylcholine which decrease heart rate and cardiac output.
7. (c) Since the use of a convex lens decreases the focal length of the eye-lens, therefore in this case, the image is formed behind retina when lens is not used.
9. (a) The cerebrospinal fluid is secreted by anterior choroid plexus and posterior choroid plexus and is found inside the ventricles of the brain and central canal of the spinal cord.
11. (cd) Vagus is 10th cranial nerve. It originates from the sides of medulla oblongata. In vertebrates it consists of sensory and motor fibres.
15. (c) Olfactory lobes are concerned with the sense of smell. The senses is very well developed in scoliodon, and dogs.
17. (b) The tectorial membrane overhangs the sensory hair in the scala media. Its properties are to determine the patterns of vibration of sound waves.
19. (d) In white fibres (medullated) impulse jumps from node to node, it is called saltatory conduction.
22. (a) Synaptic fatigue is a temporary suspension of impulse transmission in the region of synapses due to exhaustion of its neurotransmitter (acetylcholine).
31. (a) Otoconia helps in balancing the body, during the change of posture when the body is imbalanced and tilted onto one side the otoconia touch the stereocilia and bend it causing the generation of nerve impulse.
32. (a) End organ of Ruffini are external receptors of heat present in skin.
45. (a) Cataract defect develops when lens becomes opaque and loses its flexibility, its density increases and it acquires amber colour.
46. (d) Eye can be moved by 6 extrinsic ocular muscles attached to its posterior wall. Two are external and internal oblique muscle while the other four are rectus muscles.
49. (a) Cornea is a transparent layer of tissue, continuous with the sclerotic that forms the front part of the vertebrate eye over the iris and lens. The cornea refracts light entering the eye onto the lens, thus assisting in the focusing of images onto the retina.

Assertion and Reason

1. (c) To maintain the unequal distribution of Na^+ and K^+ ion, the nerves uses chemical energy in form of ATP to actively transport Na^+ ion out of cell and more K^+ inside the cell.
2. (c) Rabies is an overwhelming encephalomyelitis and includes severe headache and high fever with excitement and depression. This disease occurs by a virus called Rhabdovirus.
3. (a) Neurotransmitters need to transmit the nerve impulses through synaptic cleft which is a small part at junction of two neuron.
4. (a) Medulla oblongata consists of accumulation of nerve cells act as vital centres of many autonomic reflexes like vomiting, coughing and sneezing.
5. (b) Anterior lobe of pituitary is called Pars distalis. It is attached to hypothalamus by hypophyseal portal vein. This portal vein called hypothalamo-hypophyseal portal vein.
6. (b) Activity of sense organs is related with two types of neurons (afferent and efferent). The neurons, which pass nerve impulses from the body organ to the brain, is called afferent neuron. The neurons, which pass nerve impulses from the brain to the body organs, are called efferent neurons.

7. (c) An extracellular fluid, called cerebrospinal fluid is present throughout the central nervous system. It affords some protection to central nervous system from injury and shock.
8. (c) The neurons and nerve fibres which conduct nerve impulse from the Central Nervous System (CNS) to the peripheral organs and tissues are called efferent neurons and efferent nerve fibres respectively. Some of the neurons and nerve fibres conduct nerve impulses to the muscles and gland to stimulate or inhibit their activities. Many of these nerve fibres cause movements of muscles. So, such neurons and nerve fibres are known as motor neurons and motor nerve fibres, respectively. The motor nerve fibres are the axons of motor neurons. All motor neurons are efferent neurons, because they conduct impulses from the CNS to the peripheral tissues *viz*, muscles and gland. The nerve fibres which reach nerve impulses to the eye muscles to control their movements are motor fibres; so also are the fibres carrying impulses to the salivary glands and controlling their secretion.
- The nerve impulses are conducted from the spinal cord to the brain by ascending nerve tracts which are the bundles of nerve fibres ascending along the white matter of the spinal cord.
9. (c) The brain and the spinal cord constitute the central nervous system. The areas of the CNS where the cell bodies of the neurons are situated, look grey and constitute the grey matter. Other areas look white and constitute the white matter of the CNS. The white matter contains only nerve fibres cruising from or to the nerve cells in the grey matter. It looks white due to the presence of myelin around the myelinated fibres. In most parts of the brain, the grey matter containing the nerve cells is situated on the surface while the white matter made of fibres is located deep inside the brain; but in the spinal cord, the grey matter is internal and white matter occurs outside.
10. (e) The nervous system of human comprises of Central Nervous System – comprises of brain and spinal cord. Peripheral Nervous System – comprises of nerves present between brain and body parts.
11. (b) The spinal cord extends downwards from the brain stem. The grey matter from a column running along the central part of the spinal canal (= neurocoel, lined with ciliated ependymal epithelium), containing the cerebrospinal fluid, running along the central part of the grey matter. Grey matter is composed of nerve cells, bodies, dendrites and synapses. The white matter forms an outer column surrounding the grey matter at its centre.
12. (a) Our eyes are the sense organs for vision. The light sensitive inner layer of eyeball called retina contain photoreceptors *viz*. rod and cone cells which convert the energy of specific wavelengths of light into action potentials of nerve fibres. Rods are sensitive even to dim light and consequently enable to see in dim light and at night. They contain a purple coloured photosensitive pigment, called rhodopsin. Rhodopsin consists of the protein scotopsin and retinene, a derivative of vitamin A which is required for proper vision and is required for the regeneration of rhodopsin after it has been exposed to light.
13. (a) Tongue is also called as gustatoreceptor and it is a receptor for taste. The receptor for gustatory sensation are located in taste buds on tongue.
14. (b) The wall of each eyeball is made up of three concentric layer-sclerotic, choroid and retina. The choroid is a highly vascular pigmented layer separating the sclerotic from the inner layer of the eyeball. It is connected in front to a thick structure called ciliary body.
- Iris is a pigmented, muscular, opaque diaphragm which extends from the ciliary body in front of a biconvex transparent lens. Iris has a small central aperture called pupil. Light passing through the cornea enters through the pupil to fall on the lens behind it. The iris has two sets of smooth muscles arranged circularly and radially around the pupil. The pupil gets constricted by the contraction of circular muscles to reduce the amount of light falling on the lens. On the contrary, the pupil gets dilated by the contraction of radial muscles to increase the amount of light falling on the lens.
15. (c) The light sensitive inner layer of eyeball called retina contain photoreceptors *viz*. rod and cone cells which convert the energy of specific wavelengths of light into action potentials of nerve fibres. Cone cells are sensitive to bright light only. So, they help to see in daylight or in a brightly illuminated room by electric lamps. Rod cells are sensitive even to dim light and consequently help to see in dim light and at night. Animals, like sparrows, which are active only in day time, have mostly cone cells in their retina and therefore they possess poor night vision.
- Ommatidia are the elongated tube like units of a compound eye present in higher invertebrates like prawns, crabs and insects. Ommatidia are crowded over a spherical surface. Each focusses the light from a small area of the object so that a mosaic of a large number of images of the adjacent areas of the object are formed by numerous ommatidia. A fusion of these images may produce a composite blurred image of the object.
16. (b) The choroid is the middle layer of eyeball which is connected in front to a thick structure called ciliary body. Thread like suspensory ligaments extend from the ciliary body and get attached to a biconvex, transparent elastic Lens. For proper vision, light rays from a visual object must be focussed sharply and precisely on the retina. In the resting eye, the ciliary muscles remain relaxed, keeping the suspensory ligaments stoutly stretched which flattens the elastic lens to reduce its curvature.
- The lens in this resting eye focusses parallel rays from distant objects (more than 6 m away) on the retina. But to increase the power of the lens for focussing divergent rays from near object on the retina, a reflex called accommodation is needed. The eye has got the property to form images of both near and far objects on the retina by changing the convexity of the lens. This is known as the power of accommodation.
17. (b)

Neural Control and Coordination

SET Self Evaluation Test

- Which one of these processes is found in animals only
[MP PMT 1994]
(a) Nervous system (b) Hormonal control
(c) Respiration (d) Diffusion
- Saltatory conduction occurs in
(a) Myelinated nerve fibres
(b) Non-myelinated nerve-fibres
(c) Both myelinated and non-myelin nerve fibres
(d) Skeletal muscle fibres
- Who got the Nobel prize for describing in detail the visual cycle
(a) Wald (b) Sherrington
(c) Young (d) Henson
- The largest cranial nerve of the body is [MP PMT 1999]
(a) Hypoglossal (b) Vagus
(c) Glossopharyngeal (d) Olfactory
- Human eyes are most sensitive to the wave length of
(a) 1000 Å (b) 5000 Å
(c) 7000 Å (d) 20 Å
- The mixed nerve is [CPMT 1994]
(a) Auditory (b) Oculomotor
(c) Facial (d) Abducens
- Diencephalon is not a control centre of
(a) Heart beat (b) Anger
(c) Hate (d) Love
- Which of the following is not found in mammalian brain
(a) Subdural space (b) Sub-arachnoid space
(c) Optocoel (d) Duramater
- Nerve impulse travels by steps [MP PMT 1998; AFMC 2003]
(a) Chemical in nature
(b) Chemical and electric in nature
(c) Physical in nature
(d) None of the above
- Which kind of waves are generated in brain during deep sleep [AFMC 2008]
(a) Alpha wave (b) Beta wave
(c) Delta wave (d) Theta wave
- In the central nervous system myelinated fibres form the, while the non-myelinated fibre cells form the..... [AIIMS 2009]
(a) Grey matter; white matter
(b) White matter; grey matter
(c) Ependymal cells; neurosecretory cells
(d) Neurosecretory cells; ependymal cells
- Which of the following are the two extra cranial nerves found in rabbit [CPMT 1993]
(a) Glossopharyngeal and hypoglossal
(b) Glossopharyngeal and spinal accessory
(c) Spinal accessory and hypoglossal
(d) Pneumogastric and hypoglossal
- The chief functional units of the nervous system are [NCERT; DPMT 1993; MP PMT 1995; Pb. PMT 2004]
(a) Neuroglia (b) Axon
(c) Neurons (d) Dendrites
- Which one of the following is spinal nerve [CPMT 1998]
(a) Hypoglossal (b) Trigeminal
(c) Olfactory (d) None of these
- Which of the following is an example of conditioned reflex [BHU 1999]
(a) Cycling
(b) Withdrawal of hand on touching a hot plate
(c) Watering of mouth at smell of food
(d) Flowing of tears while cutting onions
- If parasympathetic nerve of the rabbit is cut then heart beat [RPMT 2001; MHCET 2002]
(a) Unaffected (b) Decreases
(c) Increases (d) Stop
- Name the cranial nerves of humans being viz., II, VII, VIII, IX [Odisha PMT 2002]
(a) Optic, auditory, facial, hypoglossal
(b) Oculomotor, auditory, abducens, hypoglossal
(c) Optic, facial, auditory, glossopharyngeal
(d) Optic, facial, abducens, glossopharyngeal
- Which set of ions are required during conduction of the nerve impulse [CBSE PMT 1991; AFMC 1995]
(a) Na and Ca (b) Ca and Mg
(c) Na and K (d) Na and Mg
- The rate of conduction in myelinated fibre of a mammal is very high because [CPMT 1992]
(a) Synapses are less frequent
(b) Action potential is faster and numerous
(c) Action potential jumps from node to node
(d) Membrane is depolarised faster
- The sequence of ear ossicles starting from the ear drum is [DPMT 1993; Pb. PMT 2000; MP PMT 2001; AFMC 2004; BHU 2005]
Or
What is the right sequence of bones in the ear ossicles of a mammal starting from the tympanum inwards
Or
The sequence of ossicles starting from outside to inside [DPMT 2007]
(a) Malleus, incus, stapes (b) Incus, malleus, stapes
(c) Malleus, stapes, incus (d) Stapes, incus, malleus
- The chemoreceptors in the body are
(a) Proprioceptors (b) Meissner's corpuscles
(c) Olfactory and taste organs (d) Free nerve endings

22. Which of the following use Radar systems in detecting the target
 (a) Birds (b) Bats
 (c) Dogs (d) Bats and dogs
23. Organs of corti are present in the cavity known as
 [NCERT; CPMT 1992, 93; MP PMT 1992, 2003, 04]
 (a) Scala tympani
 (b) Helicotrema
 (c) Reissner's membrane
 (d) Scala media (Cochlear canal)
24. Anosmia is
 (a) Related to ear disease (b) Related to eye disease
 (c) Related to tongue (d) Loss of sense of smell
25. The membranous labyrinth is concerned with
 (a) Hearing (b) Balancing
 (c) Sound production (d) Hearing and balancing
26. A receptor
 (a) Is the first segment of a reflex arc
 (b) Initiates nerve impulses
 (c) Responds to only one type of stimulation
 (d) All of these
27. Which of the following sense organs are unique in fishes (Scoliodon)
 [KCET 1999; CPMT 2003; MHCET 2004]
 (a) Optic organs (b) Olfactory organ
 (c) Muscle system (d) Lateral line sense organs
28. Ear is most sensitive to
 (a) 20 cycles/sec (b) 1,000 cycles/sec
 (c) 10,000 cycles/sec (d) 40,000 cycles/sec
29. In mammals, the lacrimal glands are concerned with secretion of
 [HP PMT 2005]
 (a) Hormones (b) Digestive juices
 (c) Enzymes (d) Tears
30. The malleus, incus and stapes are the modified bones ofrespectively
 [MP PMT 2004]
 (a) Articular, hyomandibular and quadrate
 (b) Quadrate, articular and hyomandibular
 (c) Articular, quadrate and hyomandibular
 (d) Quadrate, hyomandibular and articular

Answers

1	a	2	a	3	a	4	b	5	b
6	c	7	a	8	c	9	b	10	c
11	b	12	c	13	c	14	d	15	a
16	c	17	c	18	c	19	c	20	a
21	c	22	b	23	d	24	d	25	d
26	d	27	d	28	b	29	d	30	c

* * *